International Journal of Research in Health and Allied Sciences

Journal home page: www.ijrhas.com

Official Publication of "Society for Scientific Research and Studies" [Regd.]

ISSN: 2455-7803 Index Copernicus value [ICV] = 68.10;

Review Article

Age Changes in the Facial Bones- A Review Article

Renu Gupta[1], Urmi Aggarwal[2], Bhavya Aggarwal[3], Divy Vashisht[4]

[1]Professor and Head, Deptt. of prosthodontics, H.P. Government Dental college, Shimla, H.P.;
[2]PG student, Department of prosthodontics, H.P. Government Dental College, Shimla, H.P.;
[3]MBBS III year student, Government Medical College, Amritsar, Punjab;
[4]Professor, Deptt. of prosthodontics, H.P. Government Dental College, Shimla, H.P.

***ABSTRACT*:**
Facial aging is a dynamic process involving the aging of soft tissues and bony structures. It has been reviewed that how the facial skeleton changes with age in both male and female subjects and what impact these structural changes may have on overall esthetics. Areas with a strong predisposition to resorption include midface skeleton particularly maxilla and its parts and mandible. The facial skeleton experiences morphological changes and an overall decrease in volume with increase in age. This in addition to decrease in facial fat leads to appearance of aged face which can be managed prosthodontically.
Key words: Nutrition, geriatric patients.

Received: 8 March, 2020 Accepted: 26 April, 2020

Corresponding author: Dr. Urmi Aggarwal, PG student, Department of prosthodontics, H.P. Government Dental College, Shimla, H.P

This article may be cited as: Gupta R, Aggarwal U, Aggarwal B, Vashisht D. Age Changes in the Facial Bones- A Review Article. Int J Res Health Allied Sci 2020; 6(5):18-22.

Introduction

Meredith defines growth as "the entire series of anatomic and physiologic changes taking place between the beginning of prenatal life and the close of senility." [(2)] Facial aging is a dynamic process involving the aging of soft-tissue and bony structures. It has been demonstrated how the facial skeleton changes with age in both male and female subjects and what impact these structural changes may have on overall facial aesthetics. [(3)] It currently is clear that certain areas of the facial skeleton undergo resorption with aging. Areas with a strong predisposition to resorption include the midface skeleton, particularly the maxilla including the pyriform region of the nose, the superomedial and inferolateral aspects of the orbital rim, and the prejowl area of the mandible. These areas resorb in a specific and predictable manner with aging.[(1)] The aging process has also been shown to affect the facial bones. Multiple studies suggest that the bony aging of the orbit and midface is a process primarily of contraction and morphologic changes.[(3)] Changes in the facial skeleton that occur with aging and their impact on facial appearance have not been well appreciated. For example, it has been thought that maxillary retrusion of the maxilla does not occur with aging in the fully dentate patient . However, contrary to this view, recent evidence clearly demonstrates that aging of the maxilla is primarily one of bone resorption. [(1)] .Human bone is subjected to several changes throughout life time. Trauma, neoplasia or inactivity can lead to a reduction of bone volume and a change in bone architecture. Normal bone metabolism is a result of a balanced relationship of bone resorption and bone formation.[(4)] The facial skeleton is generally believed to expand continuously throughout life. This is reflected in the progressive increase in certain facial anthropometric measurements with age such as the nasion-to-anterior nasal spine and the facial width. [(1)] Selective resorption occurs in specific areas of the adult facial bone. Contrary to conventional beliefs, remodelling of the facial skeleton occurs unabated regardless of the state of the dentition, although the loss of dentition significantly accelerates bony resorption of the maxilla and mandible. The application of this knowledge to selectively correct areas of reduced bone projections in patients with deficiencies either inherent or due to aging is discussed. [(1)]

BACKGROUND

Age-related morphological changes of the bone

Bone consists of mineral (mainly hydroxyapatite), organic (90% collagen type I, 10% non-collagenous proteins) and water phases. Takahashi reported that women begin. life with significantly less bone than men. The human bone underlies remodelling throughout the whole lifetime. As a result of normal bone remodelling in the adult human skeleton, between 5 and 10% is replaced per year [(4)] Throughout life, bone tissue is continuously being formed, removed, and replaced. [(5)] With increasing age, bone becomes porous; harvesian canals and canaliculi become plugged and the number of empty osteocyte lacunae increases [(4)] A decrease of osteoblast activity is observed in the 6th decade, resulting in an increase of the surface of inactive osteoid [(4).] The osteoclast is the major agent of bone resorption. Osteoclast is derived from the fusion of cells of the mononuclear phagocyte system. The most plausible mechanism for osteoclast formation is that bone-lining alter bone locally in such a way as to lead to its phagocytic recognition by mononuclear phagocytes. These cells then accumulate on the altered bone surface, commence digestion, and fuse.[(13)] These changes occur exclusively in deeper layers of the bone, not in superficial layers, which indicates that this is rather due to the age of bone than the age of the subject Two urinary markers (urinary total and free deoxypyridinoline) are thought to be specific for bone resorption, however, no change was observed with age.[(4)]

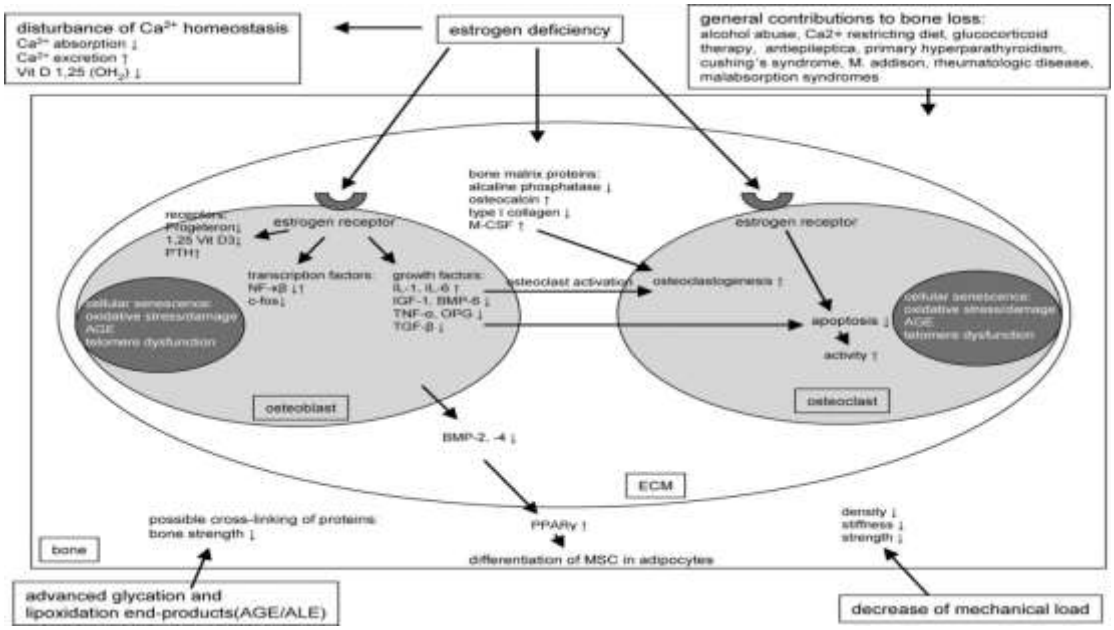

PERIORBITAL REGION

The orbital aperture increases with age, in both area and width. Resorption is, however, uneven and site specific. The superomedial and inferolateral aspects of the orbital rim, in particular, recede more, although the changes occur at different rates (Fig. 1). The inferolateral orbital rim changes manifest earlier, by middle age, whereas in the superomedial quadrant, recession may be noted only in old age. The inferomedial quadrant of the orbit also has a tendency to recede in old age, especially in males. In contrast, the central part of the superior and inferior orbital rims is more stable, with little if any resorption occurring with age.[(1)]

Fig. 1 Orbital aging. The superomedial and inferolateral aspects of the orbit have the greatest tendency to resorb. This contributes to the stigmata of periorbital aging such as increased prominence of the medial fat pad, elevation of the medial brow, and lengthening of the lid cheek junction

MIDFACE REGION

The midface skeleton is formed by the maxilla in the medial and middle thirds and by the body and arch of the zygoma in the lateral third. Contrary to conventional orthodontic teaching, it has been clearly demonstrated recently that midface retrusion does occur with aging in dentulous patients . The rate of bony resorption in the midface, however, is not uniform. The maxilla is more susceptible to age-related loss than the zygoma.[1]

Maxilla: Two studies-" found that anterior nasal spine (ANS) moved anteriorly, whereas two other investigators'":'" suggest that no change in palatal length occurred. [2]Mendelson et al. confirmed the important finding that the maxilla retrudes with aging and quantitated the changes. The maxillary angle decreased by about 10 ° between young (age \ 30 years) and old (age [60 years) individuals. [1]

PERINASAL CHANGES

Shaw and Khan found that the piriform aperture, resembling the situation of the orbital aperture, enlarges with aging as the edges of the ‘‘nasal’’ bones recede with age. Similarly, bone loss is not uniform, with the greatest resorption occurring in the ascending process of the maxilla. The posterior displacement of the bone rim is greatest at the lower pyriform aperture, which is the critical area for support of the lateral crurae and the external nasal valves.[!] The anterior nasal spine also recedes with aging (although at a slower rate), and this reduced skeletal support contributes to retraction of the collumella, with downward tip rotation and apparent lengthening of the nose with aging.[1]

The loss of bone in the pyriform area weakens the support of the lateral crura. Deepening of the maxilla results in posterior positioning of the nasolabial crease and adjacent upper lip

LOWER FACE (MANDIBLE)

- Bigonial Width and Ramus Breadth : Bigonial width did not change significantly with increasing age for either male or female subjects. Ramus breadth did not change significantly with increasing age for either male or female subjects.[3]
- Ramus Height : The ramus height decreased significantly with age for both male and female study populations. Male subjects had a statistically significant de- crease from the middle age group to the old age group . Female subjects had a statistically significant decrease from the middle age group to the old age group.[3]
- Mandibular Body Height : The mandibular body height decreased significantly with age for both male and females.[3]
- Mandibular Body Length : The mandibular body length decreased significantly with age for both male and females.[3]
- Mandibular Angle**:** The mandibular angle significantly increased with age for both male and females.[3]
  These standard parameters, based on linear measurements, will fail to detect in between areas of reduced skeletal projection such as the prejowl region of the mandible that develops into an area of relative concavity and contributes to the appearance of jowls.

PROSTHODONTIC CONSIDERATIONS: MANAGEMENT OF RESORBED MAXILLA AND MANDIBLE

HOLLOW COMPLETE DENTURE:

The severely resorbed maxillary and mandibular edentulous arches that are narrow and constricted with increased inter-arch space provide decreased support, retention, and stability and pose a clinical challenge to the success of complete denture prostheses. The consequent weight of the processed complete denture only

compromises them further. A technique for the fabrication of a hollow maxillary complete denture in situation where there is excessive resorption of the maxillary residual alveolar ridge and thereby greatly reducing the weight of an exceptionally heavy maxillary denture. [15]

HOLLOW DENTURE USING MONOPLANE TEETH:

Extreme resorption in one or both of the residual alveolar ridges accompanied by resilient maxillary denture bearing tissues in the edentulous patient presents a difficult restorative problem and may lead to problems with prosthetic rehabilitation. This article highlights on a technique for the fabrication of a maxillary denture with a part of it made hollow in a situation where there is excessive resorption in a part of maxillary residual alveolar ridge due to the constant impingement of the opposing teeth in that area. Vinyl-polysiloxane putty material is used in this technique as a spacer to create the hollow cavity inside this area .[1]

LOST SALT TECHNIQUE:

The maxillary trial denture was flasked and dewaxed in the conventional manner. Half of the heat cure PMMA , in dough stage was positioned accurately over the dewaxed mould and then salt crystals were placed over it. Above that, the remaining heat cure resin was packed and cured at 74 degree C for 7-8 hours. Cured denture was retrieved and 2 holes were made in the thickest palatal area. All the residual salt crystals were removed by flushing water with the high pressure syringe through the holes. After making sure that all the salt crystals have been removed, the escape holes were closed with autopolymerizing resin .The hollow cavity seal was verified by immersing the denture in water, if no air bubbles are evident, an adequate seal is confirmed. The dentures were inserted in the patient's mouth and instructions regarding care, hygiene and maintenance were given.

ADMIXED IMPRESSION TECHNIQUE:

The primary impressions were made using impression compound. Maxillary custom tray was fabricated using a full spacer design with additional wax relief over the anterior ridge, incisive papilla, mid-palatine raphe and tuberosity areas. Mandibular custom tray was fabricated to provide a space of 4 mm using two wax spacers for the admix impression material. Maxillary secondary impression was made using zinc oxide eugenol impression paste. The mandibular secondary impression was made using an admix of three parts by weight of impression compound and seven parts by weight of tracing compound. [18]

ALL GREEN TECHNIQUE: In this technique, the primary impression was recorded using admixed technique due to its lower compressibility and better flow characteristics. Spacer design covered crest of residual ridge to minimize stresses on them leaving the buccal shelf area. Custom tray so prepared was used to record functional form of the primary stress-bearing area and anatomic form of the area that cannot withstand functional loading. Low fusing impression compound was used to selectively exert pressure, by restricting the flow of impression material in the stress bearing area and scraping out the material from nonstress bearing areas. Tray was held by placing two fingers on the tray in the buccal shelf area and the thumb supporting the chin without exerting pressure on any part of tray. Incremental loading was done for the ease of molding all borders perfectly. Reheating of the intaglio surface was avoided to ensure that there is no differential loading of tissues caused by the flow of the material. [18]

CONCLUSION:

The facial skeleton has a profound effect on an individual's appearance. Facial aging results from a combination of soft tissue and bony changes, with bone loss in specific areas of the facial skeleton contributing significantly to the features of the aging face. [1] The facial skeleton experiences morphologic change and an overall decrease in volume with increasing age. This results in decreased support and projection of the soft-tissue envelope. This in addition to the decrease in facial fat leads to the appearance of the aged face. [3] which can be managed prosthodontically.

REFERENCES:

1. Mendelson B., Wong C.H. Changes in the facial skeleton with aging: Implications and clinical applications in facial rejuvenation. Aesth Plast Surg (2012) 36:753-760.
2. Bishara S.E. ,Ortho D., Treder J.E.,Jakobsen J.R. Facial and dental changes in adulthood. Am J Orthod Dentofac Orthop 1994; 106: 175-86.
3. Shaw B.R.,Katzel E.B.,Koltz P.F., Yaremchuk M.J., Girotto J.A., Kahn D.M., Langstein H.N. Aging of the facial skeleton: Aesthetic implications and rejuvenation strategies. Plast. Reconstr. Surg. 127:374, 2011.
4. Kloss F.R., Gassner R. Bone and aging: Effects on the maxillofacial skeleton. Experimental Gerontology 41(2006) 123-129.
5. Sveikata K., Balciuniene I., Tutkuviene J. Factors influencing Face aging:Literature Review.Stomatologija,Baltic Dental and Maxillofacial journal,13: 113-5, 2011.

6. Nedelman C.I., Bernick S. The significance of age changes in human alveolar mucosa and bone. The journal of prosthetic dentistry May 1978, vol. 39,Number 5.
7. Lux C.J., Burden D., Conradt C., Komposch G. Age related changes in the sagittal relationship between maxilla and mandible.European Jornal of orthodontics 27(2005) 568-578.
8. Manson J.D.,Lucas R.B. A Microradiographic study of Age changes in human mandible. Arch. oral Biol. Vol 7, pp. 761-769, 1962.
9. Atkinson P.J., Woodhead C. Changes in human mandibular structure with age. Archs oral Biol. Vol. 13, pp. 1453-1463, 1968.
10. Pessa J.E., Slice D.E., Hansz K.R., Broadbent T.H., Rohrich R.J. Aging and shape of the mandible, Volume 121, Number 1.
11. Pessa J.E., Zadoo V.P., Mutimer K.L.,Haffner C., Yuan C., Dewitt A.I., Garza J. R. Relative Maxillary retrusion as a natural consequence of aging: Combining skeletal and soft tissues changes into an integrated model of midfacial aging. Plastic and reconstructive surgery, July 1998.
12. Pessa J.E. An algorithm of facial aging: Verification of Lambro's theory by 3D stereolithography, with reference to the pathogenesis of midfacial aging, Scleral show, and the lateral suborbital trough deformity. Plastic and reconstructive surgery, August 2000.
13. TJ C. The cellular basis of bone resorption. 01 September, 1980, (151) : 283-293.
14. Kumar U.K.,Murgod S. Hollow complete denture for resorbd ridges. Int J oral Health Sci 2018; 8: 60-2.
15. Nandal S., Rathee M. Management of severely resorbed ridgewith modified light weight hollow denture and monoplane teeth- A Case Report. Internation journal of development research, Vol 4, Isssue 10,pp. 2001-2004, October 2014.
16. Aggarwal H., Jurel S.K., Singh R.D.,Chand P., Kumar P. Lost salt technique for severely resorbed alveolar ridges: An innovative approach.Contemp Clin Dent 2012;3:352-5.
17. Manoj S.S., Chitre V., Aras M. Management of compromised ridges : A case report.J india prosthodont Soc. 2011June; 11(2) ; 125-129.