

Original Research

Is topical 70% Trichloroacetic acid effective in treating patients with seborrhoeic keratosis?

Roohi Sharma¹, Reeta Gupta², Pavan Malhotra³

¹Assistant Professor, ³Professor & Head, Department of Pharmacology and Therapeutics, ASCOMS, Jammu, J & K, India;

²Professor, Department of Dermatology, Venerology and Leprology, ASCOMS, Jammu, J & K, India;

ABSTRACT:

Aims & Objective: The present research was aimed for evaluating the therapeutic effectiveness of topical 70% Trichloroacetic acid effective in treating patients with seborrhoeic keratosis. **Materials & methods:** For the present research, analysis of 20 patients with confirmed diagnosis of SKs was enrolled. A Performa was made and clinical and demographic profile of all the patients was tabulated. Preoperative assessment was done in all the patients. Three applications of 70% TCA was done at Baseline, 2 weeks and 4 weeks. Final follow-up was done at 10 weeks. Grading of the lesions was done according to the severity of lesion. Recording of all the results was done in Microsoft excel sheet followed by analysis with SPSS software. **Results:** Average age of the subjects was 42.1 years. 65 percent of the patients were males while 35 percent of the patients were females. During the first visit, 80 percent of the patients had severe grade of lesions while after first application (at second visit), 60 percent of the patients had severe grade of lesions. During the third visit (4 weeks), 15 percent, 40 percent and 45 percent of the patients had mild, moderate and severe grade of lesion respectively while at the final fourth visit, 20 percent, 45 percent and 35 percent of the patients had mild, moderate and severe grade of lesion respectively. **Conclusion:** From the above results, the authors conclude that TCA is a safe line of treatment for treating SKs patients.

Key words: Seborrhoeic keratosis, Trichloroacetic acid.

Received: 2 May 2019

Accepted: 17 May 2019

Corresponding Author: Dr. Roohi Sharma, Assistant Professor, Department of Pharmacology and Therapeutics, ASCOMS, Jammu, J & K, India

This article may be cited as: Sharma R, Gupta R, Malhotra P. Is topical 70% Trichloroacetic acid effective in treating patients with seborrhoeic keratosis?. Int J Res Health Allied Sci 2019; 5(4):112-114.

INTRODUCTION

Seborrhoeic keratosis (SKs) show a great clinical variability, but even on the histologic level, several subtypes can be defined: hyperkeratotic type, acanthotic type, reticular/adenoid type, clonal type, irritated type, melanoacanthoma, and Verrucous SK with keratoacanthoma-like features. SKs are one of the most common benign cutaneous neoplasms encountered in ambulatory dermatology practice, estimated to affect at least 20 percent of the adult population, especially older adults.¹⁻³

The most common sites affected are the trunk and head/neck region, although any cutaneous site may be affected other than palms and soles. They typically present as round or oval, sharply demarcated papules or plaques, often with a keratotic (rough) surface

texture that appears to be "stuck on" the surface of the skin; the color of SKs may range from light tan to dark brown, and the size is typically between 0.5cm to 1.5cm; however, individual lesions may be smaller or larger. Some SKs may appear with a surface texture that is smooth, waxy, or very flat (almost macular), the latter occurring especially in SKs that appear initially as a lentigo.^{4, 5} Patients have wide ranges of motivations for treating or removing SKs, including embarrassment from the stigmatizing appearance of the lesion, physical irritation or pruritus, and a desire to look younger. Lesions that are inflamed, bleeding, ulcerated, or sufficiently irritated should be further characterized by a biopsy or excision to rule out malignancies.^{6- 8} Therefore; the present research was aimed for evaluating the therapeutic effectiveness of

topical 70% Trichloroacetic acid effective in treating patients with seborrhoeic keratosis.

done in Microsoft excel sheet followed by analysis with SPSS software.

MATERIALS & METHODS

For the present research, analysis of 20 patients with confirmed diagnosis of SKs was enrolled. A Performa was made and clinical and demographic profile of all the patients was tabulated. Preoperative assessment was done in all the patients. Three applications of 70% TCA was done at Baseline, 2 weeks and 4 weeks. Final follow-up was done at 10 weeks.

Exclusion criteria included:

- Patients beyond 65 years of age,
- Patients less than 18 years of age,
- Patients with history of any systemic illness,
- Patients with any known drug allergy

Grading of the lesions was done according to the severity of lesion. Recording of all the results was

RESULTS

Average age of the subjects was 42.1 years. 65 percent of the patients were males while 35 percent of the patients were females. 65 percent of the patients were married. In 60 percent of the patients had mean duration of symptoms of less than 2 years. 20 percent of the patients were diabetic while 10 percent of the patients were hypertensive. During the first visit, 80 percent of the patients had severe grade of lesions while after first application (at second visit), 60 percent of the patients had severe grade of lesions. During the third visit (4 weeks), 15 percent, 40 percent and 45 percent of the patients had mild, moderate and severe grade of lesion respectively while at the final fourth visit, 20 percent, 45 percent and 35 percent of the patients had mild, moderate and severe grade of lesion respectively.

Table 1: Clinical and demographic

Parameter	Value
Mean age (years)	42.1
Males (%)	65
Females (%)	35
Married marital status (%)	65
Unmarried marital status (%)	35

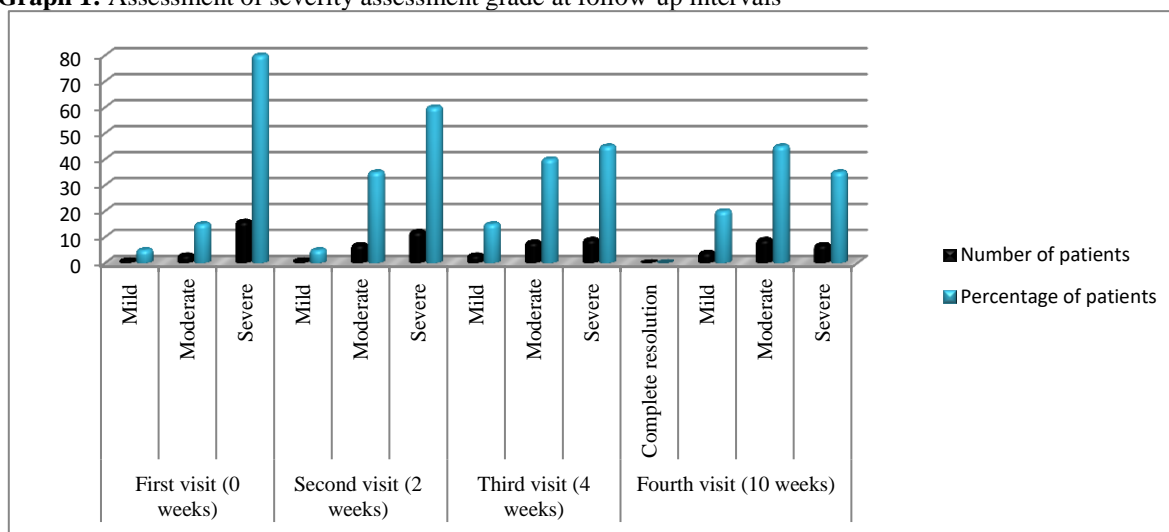
Table 2: Duration of symptoms

Duration of symptom	Number of patients	Percentage
Less than 2 years	12	60
2 to 4 years	6	30
More than 4 years	2	10
Total	20	100

Table 3: Diabetic and hypertensive status

Diabetic and hypertensive status	Number of patients	Percentage
Diabetes	4	20
Hypertension	2	10

Graph 1: Assessment of severity assessment grade at follow-up intervals



DISCUSSION

Seborrheic keratosis (SK) is the most common skin tumor seen by dermatologists in everyday practice. Although the lesions are mostly benign, many patients still elect to have asymptomatic SK removed. Seborrheic keratoses are common, benign, pigmented epidermal tumors. Many terms such as senile wart, melanoacanthoma, basal cell papilloma, senile keratosis and seborrheic wart have been applied, but seborrheic keratosis is the most widely accepted term. These usually develop after the age of 50 years although occasionally, seen in young adulthood without any sexual predilection. The common site of involvement includes the trunk, particularly the interscapular area, sides of the neck, the face and the arms. The tumors are not, however, seen on the mucous membranes. Lesions appear as coin-like, sharply demarcated, exophytic lesions and are “stuck on the skin” with a verrucous, rough, dull or punched-out surface. Flat lesions often have a smooth surface and are scarcely elevated above the surface of the skin.⁷⁻¹⁰ Therefore; the present research was aimed for evaluating the therapeutic effectiveness of topical 70% Trichloroacetic acid effective in treating patients with seborrhoeic keratosis.

In the present study, average age of the subjects was 42.1 years. 65 percent of the patients were males while 35 percent of the patients were females. 65 percent of the patients were married. In 60 percent of the patients had mean duration of symptoms of less than 2 years. 20 percent of the patients were diabetic while 10 percent of the patients were hypertensive. Chun EY et al evaluated the clinical effects of focal TCA peel on pigmented lesions in dark-skinned patients. An analysis was conducted of 106 patients with benign pigmented lesions who were treated using focal TCA peel. Seborrheic keratosis was treated with 65% focal TCA peel, solar lentigines, and freckles with 50% to 65% focal TCA peel, and melasmas with 10% to 50% focal TCA peel. Patients had Fitzpatrick skin types IV-V. Patient treatment data indicated that 19 of 23 (83%) patients with seborrheic keratosis, 42 of 49 (86%) patients with solar lentigines, 8 of 14 (58%) patients with freckles, and 11 of 20 (55%) patients with melasma experienced a good clinical response. Good satisfaction rates in the seborrheic keratosis, solar lentigines, freckles, and melasma groups were recorded. No significant complications were observed. The focal TCA peel method presented in this study is a safe and effective modality for the treatment of benign pigmented lesions with no significant complications.¹¹

In the present study, during the first visit, 80 percent of the patients had severe grade of lesions while after first application (at second visit), 60 percent of the patients had severe grade of lesions. During the third visit (4 weeks), 15 percent, 40 percent and 45 percent of the patients had mild, moderate and severe grade of lesion respectively while at the final fourth visit, 20 percent, 45 percent and 35 percent of the patients had

mild, moderate and severe grade of lesion respectively. Dayal S et al assessed the clinical efficacy, safety and reduction in Melasma Quality of Life (MELASQOL) on combining 20% TCA peel with 5% ascorbic acid cream in epidermal melasma. Combination of 20% TCA peel with topical 5% ascorbic acid is a highly effective, safe and promising therapeutic option in treatment of melasma which significantly improves the QoL.¹²

CONCLUSION

From the above results, the authors conclude that TCA is a safe line of treatment for treating SKs patients.

REFERENCES

1. Cuevas P, Angulo J, Salguero I, et al. : Clearance of seborrhoeic keratoses with topical dobesilate. *BMJ Case Rep.* 2012;2012.
2. Wat H, Dytoc M: Off-label uses of topical vitamin D in dermatology: a systematic review. *J Cutan Med Surg.* 2014;18(2):91–108.
3. Wood LD, Stucki JK, Hollenbeak CS, Miller JJ. Effectiveness of cryosurgery vs curettage in the treatment of seborrheic keratoses. *JAMA Dermatol.* 2013;149(1):108–9.
4. Wollina U: Seborrheic Keratoses - The Most Common Benign Skin Tumor of Humans. Clinical presentation and an update on pathogenesis and treatment options. *Open Access Maced J Med Sci.* 2018;6(11):2270–5.
5. Luong Kv, Nguyễn LT: The roles of vitamin D in seborrhoeic keratosis: possible genetic and cellular signalling mechanisms. *Int J Cosmet Sci.* 2013;35(6):525–31.
6. Al-Waiz MM, Al-Sharqi AI. Medium-depth chemical peels in the treatment of acne scars in dark-skinned individuals. *Dermatol Surg.* 2002;28:383–387.
7. Monheit GD. Medium-depth chemical peels. *Dermatol Clin.* 2001;19:413–425, vii.
8. Khunger N. Standard guidelines of care for acne surgery. *Indian J Dermatol Venereol Leprol.* 2008;74(Suppl):S28–S36.
9. Lu'o'ng Kv, Nguyn LT. The roles of vitamin D in seborrhoeic keratosis: possible genetic and cellular signalling mechanisms. *Int J Cosmet Sci.* 2013;35(6):525–31.
10. Gurel MS, Aral BB. Effectiveness of erbium: YAG laser and cryosurgery in seborrheic keratoses: Randomized, prospective intraindividual comparison study. *J Dermatolog Treat.* 2015;26(5):477–80.
11. Chun EY et al Focal trichloroacetic acid peel method for benign pigmented lesions in dark-skinned patients. *Dermatol Surg.* 2004 Apr;30(4 Pt 1):512-6; discussion 516. doi: 10.1111/j.1524-4725.2004.30166.x.
12. Dayal S, Sahu P, Yadav M, Jain VK. Clinical Efficacy and Safety on Combining 20% Trichloroacetic Acid Peel with Topical 5% Ascorbic Acid for Melasma. *J Clin Diagn Res.* 2017;11(9):WC08-WC11.