

International Journal of Research in Health and Allied Sciences

Journal home page: www.ijrhas.com

Official Publication of "Society for Scientific Research and Studies" [Regd.]

ISSN: 2455-7803

Index Copernicus value [ICV] = 68.10;

ORIGINAL RESEARCH

Clinical evaluation of Trigeminal Neuralgia in outpatient clinic - Diagnosis and treatment

Abdul Rahman Al-Atram

Professor, Department of Psychiatry, College of Medicine, Majmaah University, Majmaah, Saudi Arabia

ABSTRACT:

Background: The aim of this study is to evaluate the use of carbamazepine as primary definitive diagnostic aid in patients with classical/idiopathic and symptomatic/pathological trigeminal neuralgia by analyzing the pain relief. Advantages of using carbamazepine is its easy availability, cost effective, non-invasive, no machine needed, simple, no specialized team needed and is itself a mode of treatment for trigeminal neuralgia as compared to MRI and CT. **Methods:** 100 patients with clinical characteristics signifying trigeminal neuralgia were included in this study in the age group of 50-65 years from both sexes who were examined clinically and radiographically. Sensory input of trigeminal nerve, gross motor input, diagnostic analgesic blocking and 0.5cc of normal saline at test site is also used to differentiate pain. All 100 patients were given tab. carbamazepine 100 mg twice daily to analyze the pain relief. **Results and Conclusion:** Clinical signs and symptoms were present in all 100 patients who were given tab. carbamazepine. 76 patients without any known cause for trigeminal neuralgia responded well so had pain relief and other 24 patients did not responded and had pain existing who on further evaluation were diagnosed with symptomatic trigeminal neuralgia due to some other irrelevant pathological causes. This suggests response to treatment with tab. carbamazepine as pain relief can be used as a universal primary definitive diagnostic aid in patients with trigeminal neuralgia. Failure to obtain any improvement with this treatment should bring the diagnosis into question? Sometimes patient is not able to afford costly investigations like MRI and CT, hence the medical management can be started with tab. carbamazepine to diagnose the condition. We recommend MRI and CT as further secondary investigations to rule out cause for symptomatic trigeminal neuralgia due to some other irrelevant pathological causes.

Keywords: Carbamazepine, Definitive Diagnostic Aid, MRI and CT, Trigeminal Neuralgia.

Received: 23 June, 2020

Revised: 25 July, 2020

Accepted: 28 July, 2020

Corresponding author: Dr. Abdul Rahman Al-Atram, Professor, Department of Psychiatry, College of Medicine, Majmaah University, Majmaah, Saudi Arabia

This article may be cited as: Al-Atram AR. Clinical evaluation of Trigeminal Neuralgia in outpatient clinic - Diagnosis and treatment. Int J Res Health Allied Sci 2020; 6(5): 133-135.

INTRODUCTION

Trigeminal neuralgia is most common type of neuralgia with incidence of 4.3 per 100,000 persons per year. TN is defined by International Association for Study of Pain [IASP] as sudden, usually unilateral, severe, brief, stabbing, lancinating, recurring pain in the distribution of one or more branches of 5th cranial nerve (1,2). It is also known as tic douloureux, trifacial neuralgia, fothergill's disease, neuralgia epileptiforme (3). Most cases of trigeminal neuralgia are idiopathic without any obvious assignable cause (4,5). According to International Headache Society [IHS] trigeminal neuralgia is a painful unilateral affliction of the face, characterized by brief electric

shock like pain limited to the distribution of one or more divisions of the trigeminal nerve (6,7). In symptomatic trigeminal neuralgia facial pain is due to involvement of 5th CN by some other disease like multiple sclerosis, aneurysm of basilar artery, tumor [acoustic or trigeminal neuroma, meningioma, epidermoid tumors] in cerebellopontine angle and meckels cave. All these forms of symptomatic trigeminal neuralgia may give rise only to pain in distribution of the 5th CN or it may produce a loss of sensation. Sinus tumors and metastatic diseases may also implicate the nerve, causing pain and gradually progressive sensory loss. Tumors of the sphenoid bone, myeloma, metastatic carcinoma, squamous cell

carcinoma and lymphoepithelioma of nasopharynx may involve branches of trigeminal nerve at their foramina of entry or exit. The ophthalmic division of the 5th CN may be involved in the wall of cavernous sinus; mandibular division may be compressed by roots of an impacted 3rd molar (8,9). Compression of the trigeminal roots by tortuous blood vessel is described by Dandy as idiopathic (10). Jannetta has observed it in most of his patients that the compression of the trigeminal roots by tortuous blood vessels and has relieved their pain by surgical decompression of the trigeminal root in the form of removing the offending small vessel from contact with the proximal portion of the nerve (11). Hughes reported cases of trigeminal neuropathy associated with scleroderma, lupus erythematosus and Sjogrens syndrome. Middle ear infections and osteomyelitis of the apex of petrous bone may spread to the ganglion and root where it can also involve the 6th cranial nerve as well called Gradenigo syndrome. Stilbamidine and trichloroethylene are known to cause sensory loss, tingling, burning and itching exclusively in the trigeminal sensory territory. Chronic nerve entrapment causes demyelination initially, followed by progressive axonal degeneration. Specific etiology of idiopathic trigeminal neuralgia is most consistently with demyelination of axons in the gasserian ganglion and dorsal root due to continued compression. In most of patient's trigeminal neuralgia is caused by compression of trigeminal nerve root close to its entry into pons "root entry zone" (12,13).

MATERIALS & METHODS

After obtaining the informed consent from all 100 patients included in this study between the age group of 50-65 years from both the sexes presenting with clinical characteristics of trigeminal neuralgia,

sensory input of trigeminal nerve is tested by lightly stroking the face with a cotton tip bilaterally in 3 regions forehead, cheek and lower jaw. Gross motor input is tested by having the patient clench teeth simultaneously palpating both masseter and temporal muscles. Diagnostic injections of a local anesthetic agent into the patients trigger zone temporarily eliminates all pain in TN. 0.5cc of normal saline is injected at test site followed by 5 minutes wait. Pain relieved, is psychogenic pain likely. If pain persists, then 0.5ml of 2% lignocaine without adrenaline is injected at surface site followed by 5 minutes wait. If pain is relieved, then therapy is directed at small nociceptor fibers. If the pain persisted, injection is given little deeper followed by 5 minutes wait. Pain relieved is considered musculo-skeletal origin. If pain did not relieved, injection is given at more proximal portion of nerve. Diagnostically; analgesic blocking clearly differentiates TN. Since triggering may relate to facial and tongue movement's incidental to chewing and swallowing, trigeminal neuralgia must be differentiated from masticatory pain that has the clinical characteristics of deep somatic rather than neuropathic pain. Masticatory pain is induced by jaw movements, and it may be intense, but true triggering by a light superficial touch and slight movement does not occur. Masticatory pain is not arrested by a conventional mandibular local anesthetic block, because the nerves mediating the pain from the joint or the masticatory muscles are not anesthetized. Patients were recommended OPG, MRI and CT as a diagnostic radiographic investigation so that secondary trigeminal neuralgia [pathological] may be diagnosed at the initial stage. All 100 patients were given tab. carbamazepine 100 mg BD and response to pain relief is analyzed.

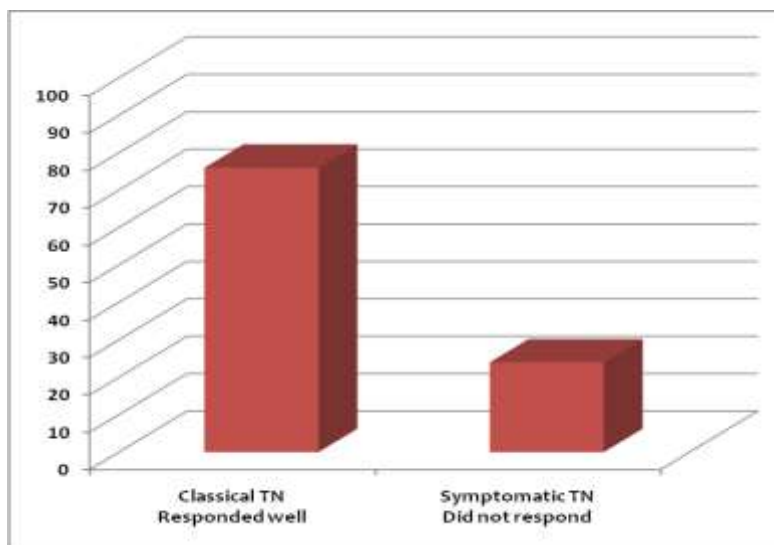


Figure 1: Response to carbamazepine and diagnostic nerve blocks.

RESULTS

After follow up period of 3 months, 76 patients without any known cause [idiopathic] responded well to tab. carbamazepine with all classical features present suggested by IHS were diagnosed with TN. 24 patients were unresponsive to tab. carbamazepine who on further evaluation are diagnosed with secondary trigeminal neuralgia [pathological] due to aneurysm of basilar artery [8 patients], multiple sclerosis [5 patients], maxillary sinus tumors [2 patients], impacted 48 tooth [2 patients], post-traumatic neuralgia [2 patients], osteomyelitis involving body + angle of mandible [1 patient] and 4 had other associated major diseases. This suggests response to treatment with tab. carbamazepine as pain relief is universal in trigeminal neuralgia and in other types of facial pain as in secondary trigeminal neuralgia [pathological], it is not useful. So carbamazepine can be used as a primary definitive diagnostic aid in patients with trigeminal neuralgia. Failure to obtain any improvement with this treatment should bring the diagnosis into question? Sometimes patient is not able to afford costly investigations like MRI and CT, hence the medical management can be started and if there is any failure of treatment, we recommend MRI and CT as further secondary investigations to rule out cause for pathological trigeminal neuralgia. Advantages of using carbamazepine as a primary definitive diagnostic aid rather than MRI and CT is its easy availability, cost effective, non-invasive, no machine needed, simple, no specialized team needed and is itself a mode of treatment.

DISCUSSION

A common consensus is lacking on how a patient presenting with trigeminal neuralgia should be managed particularly concerning the need of investigations with vast differential diagnosis of TN which includes Post-traumatic neuralgia, Cracked tooth syndrome, Cranial herpetic syndrome, Costen's syndrome, Post-zoster neuralgia, Tolosa-hunt syndrome, Jacods petro-sphenoidal syndrome, Raeder's para-trigeminal syndrome, Migrainous neuralgia, Carotidynia, Sphenopalatine neuralgia, Atypical facial neuralgia, Rochon-duvigneau syndrome, Jacod-rollet syndrome, Foix-jefferson syndrome. Pathological trigeminal neuralgia presents with the same triggering paroxysmal pains, but between pain episodes other symptoms may persist. These other symptoms relate to the pathological condition that is responsible for neuralgia. Eg; if an intracranial tumor is responsible, there may be a diminished corneal reflex, masseter muscle weakness, facial muscle weakness or hypoesthesia apart from trigeminal neuralgia. It is very common for these patients to undergo indiscriminate dental extractions on the affected side as it presents like tooth pain which is at times difficult to identify properly. So

some patients loose a few or all the teeth to the midline on the side of pain (14).

ACKNOWLEDGMENT

Author's conflict of interest disclosure: The authors stated that there are no conflicts of interest regarding the publication of this article.

REFERENCES

1. Merskey H, Bogduk N (1994). Classification of chronic pain: Description of chronic pain syndromes and definition of pain terms (2nd ed). IASP Press, Seattle.
2. Gerhard HF, Christopher FT, Joseph CM (1984). Trigeminal neuralgia; Current concepts regarding etiology and pathogenesis. Arch Neurol 41: 1204-07.
3. Fothergill J (1776). Of a painful affection of the face. London: Medical Society of London.
4. Ameli NO (1756). Avicenna and trigeminal neuralgia. J Neurol Sci 2: 105-07.
5. Andre NA (1756). Observations. College et. de l' Academie Royale de Chirurgie. Paris: Delaguette.
6. Olesen J (1988). Classification and diagnostic criteria for headache disorders, cranial neuralgias and facial pain (1st ed). Cephalgia 8 (Suppl): 1-96.
7. Headache Classification Subcommittee of the International Headache Society (2004). The international classification of headache disorders (2nd ed). Cephalgia 24 (Suppl 1): 9-160.
8. Katusic S, Beard CM, Bergstralh E, Kurland LT (1990). Incidence and clinical features of trigeminal neuralgia. Rochester, Minnesota, 1945-1984. Ann Neurol 27(1): 89-95.
9. Cruccu G, Biasiotta A, Galeotti F, et al (2006). Diagnosis of trigeminal neuralgia: A new appraisal based on clinical and neurophysiological findings. In: Cruccu G, Hallett M (Eds). Brainstem function and dysfunction. Amsterdam, the Netherlands: Elsevier: 171-86.
10. Dandy WE (1934). Concerning the cause of trigeminal neuralgia. Am J Surg 24: 447-55.
11. Jannetta PJ (1967). Arterial compression of trigeminal nerve at the pons in patients with trigeminal neuralgia. J Neurosurg 26: 159-62.
12. White JC, Sweet WH (1969). Pain and the neurosurgeon. Springfield (III); Charles C. Thomas.
13. Kugelberg E, Lindblom U (1959). The mechanism of the pain in trigeminal neuralgia. J Neurol Neurosurg Psychiat 22: 36-43.
14. Nurmikko TJ, Eldridge PR (2001). Trigeminal neuralgia- pathophysiology, diagnosis and current treatment. Br J Anaesth 87 (1): 117-32.