

# International Journal of Research in Health and Allied Sciences

Journal home page: [www.ijrhas.com](http://www.ijrhas.com)

Official Publication of "Society for Scientific Research and Studies" [Regd.]

ISSN: 2455-7803

## Original Research

### Evaluation of dental implant placement site in anterior maxilla- A clinical study

Ashish Pandey<sup>1</sup>, Shalini Pandey<sup>2</sup>, Gagandeep Kaur<sup>3</sup>, Guruprasad G M<sup>4</sup>, Tanya Batra<sup>5</sup>, Laxmikant R.Hedau<sup>6</sup>

<sup>1</sup>Head of the Department of Prosthodontics, Daswani Dental College & Research Centre, Kota Rajasthan;

<sup>2</sup>Senior lecturer, Dept of Prosthodontics, Hazaribagh College of Dental Sciences, Jharkhand;

<sup>3</sup>BDS final year, ITS Dental College, Murad nagar, Ghaziabad, U.P., India

<sup>4</sup>Professor & HOD, Department of Oral Surgery. Sharavathi Dental College, Shivamogga, Karnataka;

<sup>5</sup>BDS (Jamia Millia Islamia New Delhi), Junior Resident MAIDS Delhi;

<sup>6</sup>BDS, VSPMDCRC Nagpur

#### ABSTRACT:

**Background:** Dental implant therapy has revolutionarized the field of dentistry. The present study was conducted to assess dental implant placement site in anterior maxilla. **Materials & Methods:** The present study was conducted on 58 patients of both genders who received dental implants in anterior maxilla. Number of canals and length and width of bone in anterior maxilla was evaluated. **Results:** Out of 58 patients, males were 30 and females were 28. Single canal was present in 36 patients, double in 12, triple in 6 and Y shaped in 4 patients. The difference was significant ( $P < 0.05$ ). The mean length in males was 12.4 mm and in females was 13.1 mm, width was 5.6 mm in males and 5.2 mm in females. The difference was significant ( $P < 0.05$ ). **Conclusion:** Authors found mean bone height in males as 12.4 mm and in females as 13.1mm and width as 5.6 mm in males and 5.2 mm in females.

**Key words:** Dental Implant, maxilla, Nasopalatine canal

Received: 28 July, 2019

Revised: 22 September, 2019

Accepted: 29 September, 2019

Corresponding author: Dr. Ashish Pandey, Head of the Department of Prosthodontics, Daswani Dental College & Research Centre, Kota Rajasthan, India

This article may be cited as: Pandey A, Pandey S, Kaur G, G M Guruprasad, Batra T, Hedau LR. Evaluation of dental implant placement site in anterior maxilla- A clinical study. Int J Res Health Allied Sci 2019; 5(5):147-150.

#### INTRODUCTION

Dental implant therapy has revolutionarized the field of dentistry. The long term survival rate of dental implants have been well documented in the literature. The survival rate of 95% in 5 years has been considered successful treatment. The maintenance of peri-implant bone tissue is essential for the long-term success of dental implants.<sup>1</sup> The most widely used parameters for measuring outcomes in implant dentistry are related to the implant, the peri-implant soft tissue, and the prosthesis, besides the subjective assessment of the patient. These parameters are related to the tissue

stability, which influences the progression of marginal bone loss (MBL) around healthy implants.<sup>2</sup>

Implant rehabilitation of the edentulous anterior maxilla remains one of the most complex restorative challenges because of several variables that affect the esthetic and functional aspects of prostheses. The intricate preexisting anatomy dictates meticulous and accurate osteotomy planning into a premaxilla reconstruction.<sup>3</sup> In the post-extraction phase, the high resorption rate of the maxilla could be jeopardized with the surgical osteotomy preparation and prosthesis retention. With progressive bone loss, the alveolar crest may approach to the anatomic structures. The nasopalatine nerve and

vessels emerge from the crest of the ridge with palatal migration of the anterior maxillary alveolus. Careful consideration is necessary when an implant is positioned in the maxillary central incisors because of the proximity of the nasopalatine canal (incisive canal) and its contents.<sup>4</sup> The present study was conducted to assess dental implant placement site in anterior maxilla.

**MATERIALS & METHODS**

The present study was conducted in the department of Prosthodontics. It included 58 patients of both genders who received dental implants in anterior maxillary

region. All patients were informed regarding the study and written consent was obtained prior to the study. The study protocol was approved from institutional ethical committee.

Information such as name, age, gender etc. was obtained. In all patients, radiographs were obtained for evaluation of number and length of nasopalatine canals and width of bone. Results thus obtained were subjected to statistical analysis. P value < 0.05 was considered significant.

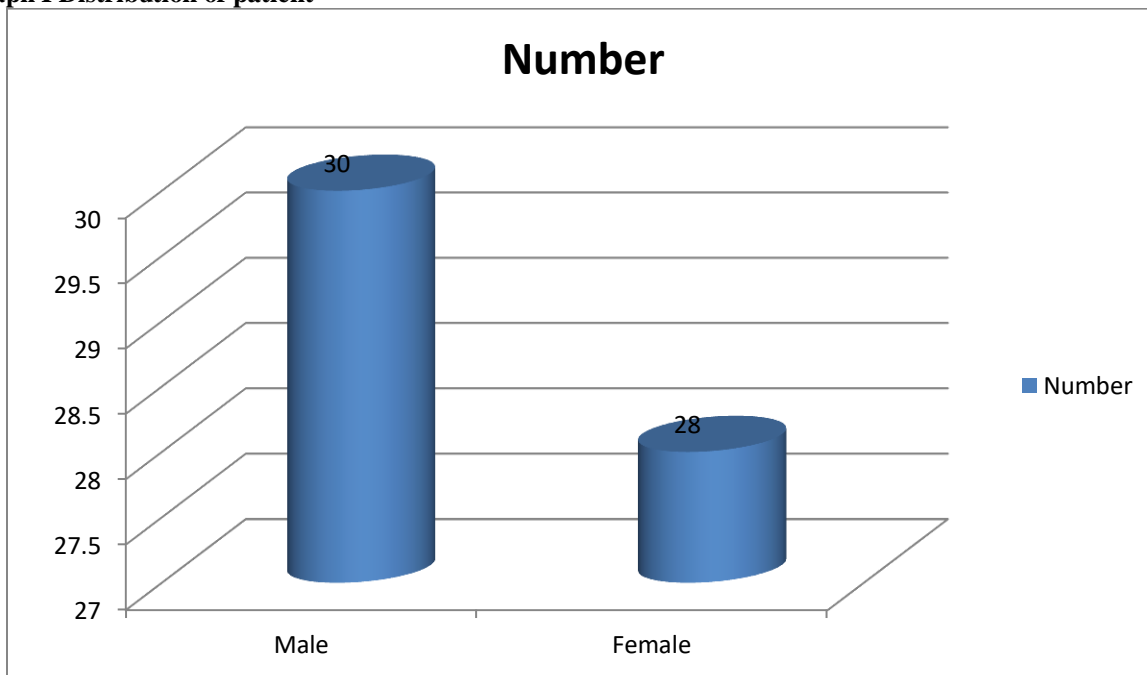
**RESULTS**

**Table I Distribution of patient**

Gender	Male	Female
Number	30	28

Table I, graph I shows that out of 58 patients, males were 30 and females were 28.

**Graph I Distribution of patient**

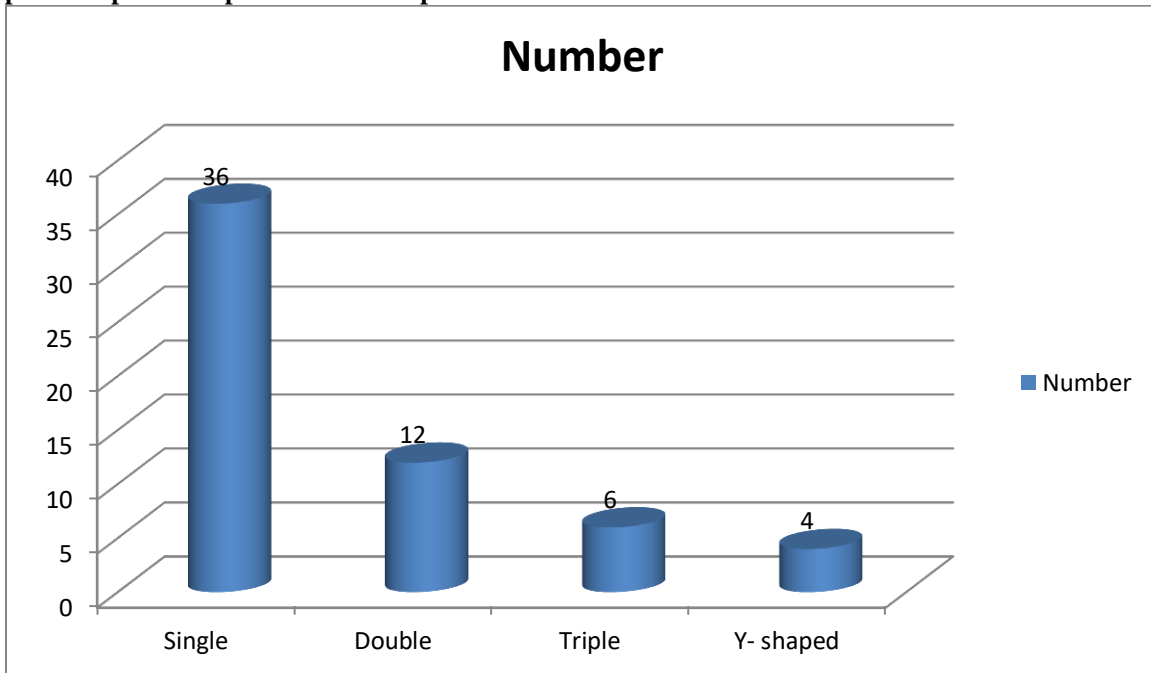


**Table II Shape of nasopalatine canal in patients**

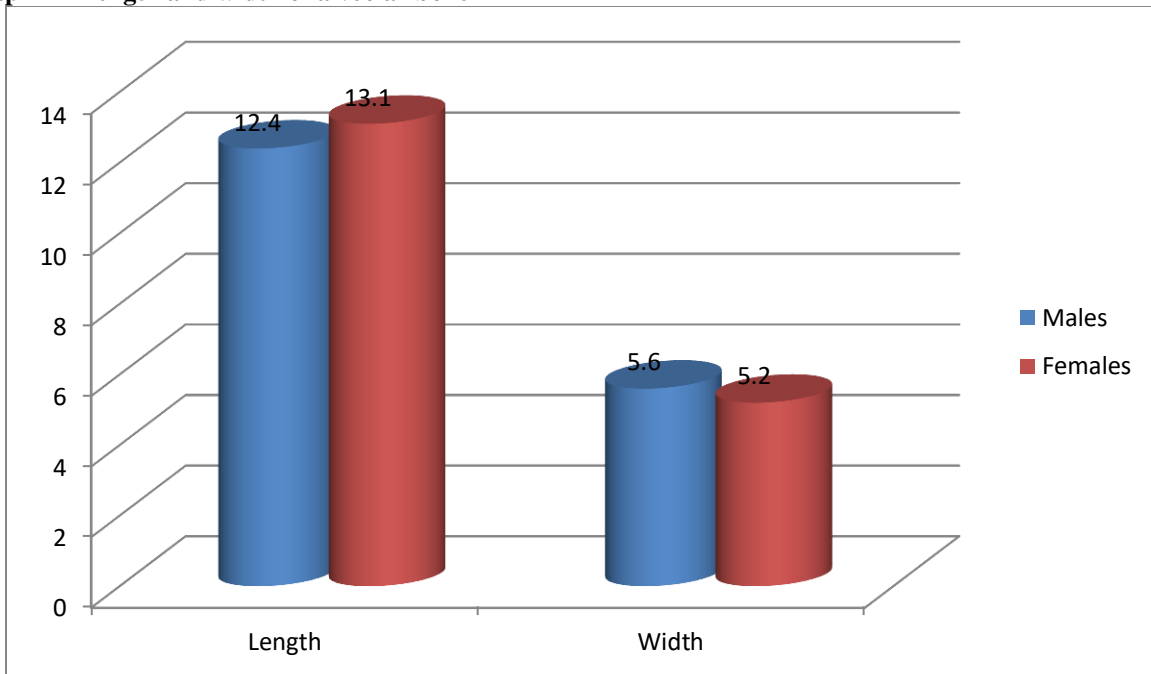
Shape	Number	P value
Single	36	0.01
Double	12	
Triple	6	
Y- shaped	4	

Table II, graph II shows that single canal was present in 36 patients, double in 12, triple in 6 and Y shaped in 4 patients. The difference was significant (P< 0.05).

**Graph II Shape of nasopalatine canal in patients**



**Graph III Length and width of alveolar bone**



Graph III shows that mean length in males was 12.4 mm and in females was 13.1 mm, width was 5.6 mm in males and 5.2 mm in females. The difference was significant ( $P < 0.05$ ).

### DISCUSSION

Tooth loss is very common and it can happen as a result of disease and trauma; therefore, the use of dental implants to provide support for replacement of missing teeth has a long and multifaceted history. Statistics

provided by the American Association of Oral and Maxillofacial Surgeons show that 69% of adults ages 35 to 44 have lost at least one permanent tooth to an accident, gum disease, a failed root canal or tooth decay. Furthermore, by age 74, 26% of adults have lost

all of their permanent teeth.<sup>5</sup> Different implant designs and procedures are being introduced constantly as Implantology continues to evolve. These new products have been subject to varying levels of research and development and clinical documentation with the implications that some materials or procedures may prove to be less reliable or safe in routine use.<sup>5</sup> Since clinicians are bound by ethical and medico-legal responsibilities, the onus is very much on the treating dentist to select the most appropriate procedure or material depending on individual circumstances.<sup>6</sup> In accordance with the current training standards guidance by the GDC, clinicians must ensure that the treatment they offer and undertake must be evidence based and patient-centered. The dentist must also use a contemporary decision-making process to critically appraise new products and techniques before using them, and must ensure they follow current clinical consensus.<sup>7</sup> The present study was conducted to assess dental implant placement site in anterior maxilla.

In present study, out of 58 patients, males were 30 and females were 28. Rosenquist et al<sup>8</sup> found that the study population comprised 44 men and 56 women with a mean age of 43.09 years. Gender of the included patients had a statistically significant influence on the dimensions of the buccal bone plate, the mean values being generally higher for male subjects. Author demonstrates decreasing values for the coronal width of the buccal bone wall in patients with missing central incisors and a time span since tooth loss of over 1 year. The age of the patients had a significant influence only on the length of the nasopalatine canal, with the mean values generally decreasing with an increasing age.

We found that single canal was present in 36 patients, double in 12, triple in 6 and Y shaped in 4 patients. The mean length in males was 12.4 mm and in females was 13.1 mm, width was 5.6 mm in males and 5.2 mm in females. Artzi et al<sup>9</sup> conducted a prospective study evaluating sensory disorders after separation of the nasopalatine nerve during removal of impacted and palatally displaced maxillary canines revealed no subjective or objective neurological impairments more than 4 weeks after the intervention. Dental implant was placed in anterior maxilla in 80 patients. The width and length of the bone found to be adequate.

The nasopalatine canal is usually described as being located in the midline of the palate, posterior to the central maxillary incisors. The funnel-shaped oral opening of the canal in the midline of the anterior palate is known as the incisive foramen, and is usually located

immediately below the incisive papilla. The canal divides into two canaliculi on its way to the nasal cavity, and terminates at the nasal floor with an opening at either side of the septum. The canal contains the nasopalatine (incisive) nerve and the terminal branch of the descending nasopalatine artery, as well as fibrous connective tissue, fat, and even small salivary glands.<sup>10</sup>

## CONCLUSION

Authors found mean bone height in males as 12.4 mm and in females as 13.1mm and width as 5.6 mm in males and 5.2 mm in females.

## REFERENCES

1. Bosse LP, Taylor TD. Problems associated with implant rehabilitation of the edentulous maxilla. *Dent Clin North Am* 1998;42:117-27.
2. Carlsson GE, Bergman B, Hedegård B. Changes in contour of the maxillary alveolar process under immediate dentures. A longitudinal clinical and x-ray cephalometric study covering 5 years. *Acta Odontol Scand* 1967;25:45-75.
3. Hoffmann KD. Anatomic considerations in the partially and fully edentulous maxilla. *Atlas Oral Maxillofac Surg Clin North Am* 1994;2:31-9.
4. Buser D, Martin W, Belser UC. Optimizing esthetics for implant restorations in the anterior maxilla: Anatomic and surgical considerations. *Int J Oral Maxillofac Implants* 2004;19 Suppl: 43-61.
5. Atwood DA. Some clinical factors related to rate of resorption of residual ridges. *J Prosthet Dent* 1962;12:441-50.
6. Bhatia A, Bains SK. Assessment of outcome of dental implant therapy in different age groups- A clinicoradiographic study. *Int J Res Health Allied Scie.* 2019; 5(1): 45-48.
7. Kraut RA, Boyden DK. Location of incisive canal in relation to central incisor implants. *Implant Dent* 1998;7:221-5.
8. Rosenquist JB, Nyström E. Occlusion of the incisal canal with bone chips. A procedure to facilitate insertion of implants in the anterior maxilla. *Int J Oral Maxillofac Surg* 1992;21:210-1.
9. Artzi Z, Nemcovsky CE, Bitlitum I, Segal P. Displacement of the incisive foramen in conjunction with implant placement in the anterior maxilla without jeopardizing vitality of nasopalatine nerve and vessels: A novel surgical approach. *Clin Oral Implants Res* 2000;11:505-10.
10. Scher EL. Use of the incisive canal as a recipient site for root form implants: Preliminary clinical reports. *Implant Dent* 1994;3:38-41.