

Original Research

TO COMPARE AND EVALUATE THE DIFFERENCE IN CLINICO-RADIOLOGICAL PARAMETERS AFTER IMPLANT PLACEMENT WITH CLINDAMYCIN IRRIGATION AND NORMAL SALINE IRRIGATION OF OSTEOTOMY SITE-AN IN VIVO STUDY

Renu Gupta¹, Niyati Arora², Divya Vashisth³, Bhavya Aggarwal⁴, Priyanka Singh², Vijay Chib²

¹Professor & Head, ²PG Student, ³Professsor, Department of Prosthodontics, HPGDC, Shimla (HP)

⁴MBBS Final year student, GMCH Amritsar

ABSTRACT:

BACKGROUND: There are many reasons for dental implant failure one of which is the development of bacteremia around implants. The salivary microflora and periodontal microflora pose a potential risk to the implants. To prevent the onset of infection at the site of implant placement prophylactic antibiotics as well as irrigation of the osteotomy sites with an antibiotic are prescribed to elevate the antibiotic concentration in blood and local environment to reduce the chance of bacterial proliferation and dissemination. **MATERIAL AND METHOD:** A total of 20 implants were placed in 10 subjects. (Group 1- osteotomy site irrigated with normal saline; Group 2- osteotomy site irrigated with clindamycin). The patients were recalled after 1 month, 2 month and 3 month after placement. **RESULTS:** It was observed that the mean pain levels, crestal bone loss and clinical peri implant infection in group irrigated with Clindamycin was less than that observed in patients irrigated with normal saline.

Key words: Clindamycin

Received: March 02, 2021

Accepted: March 25, 2021

Corresponding Author: Dr. Niyati Arora, PG Student, Department of Prosthodontics, HPGDC, Shimla (HP)

This article may be cited as: Gupta R, Arora N Vashisth D, Aggarwal B, Singh P, Chib V, To compare and evaluate the difference in Clinico-Radiological parameters after implant placement with Clindamycin irrigation and Normal saline irrigation of osteotomy site-an in vivo study. Int J Res Health Allied Sci 2021;7(2):106- 110

INTRODUCTION

If you don't like bacteria, you're on the wrong planet."

Modern dentistry aims to restore the comfort and health of the stomatognathic system and dental implants have emerged as a promising option for this purpose presenting with multiple therapeutic possibilities, high predictability of success and are considered to be a reliable approach to replace missing teeth regardless of the disease or injury of the stomatognathic system.⁽¹⁾

There are many reasons for dental implant failure one of which is the development of bacteremia around implants. Oral postoperative infections in healthy patients are commonly wound infections caused by endogenous aerobic and anaerobic microorganisms in the oral cavity (Heimdahl and Nord 1990). Some

dental implant failures can be due to contamination from bacteria while inserting the implant. The salivary microflora and periodontal microflora pose a potential risk to the implants. Infections around biomaterials are difficult to treat, and most of the infected implants have to be replaced.⁽²⁾

Hence, to prevent the onset of infection at the site of implant placement prophylactic antibiotics as well as irrigation of the osteotomy sites with an antibiotic are prescribed to elevate the antibiotic concentration in blood and local environment to reduce the chance of bacterial proliferation and dissemination.⁽³⁾

One of the antibiotics, Clindamycin reaches high concentrations in saliva, GCF, and bone. Several studies have shown that the concentration of clindamycin in these tissues is approximately 40% to

50% of the concentration in serum. ⁽⁴⁾ Clindamycin is the only proven antibiotic that reduces the adherence of bacteria to the epithelia. ⁽⁵⁾

MATERIAL AND METHOD

The study was conducted on subjects visiting the Department of Prosthodontics and Crown & Bridge, Himachal Pradesh Government Dental College and Hospital, Shimla. A total of 20 implants were placed in 10 subjects.

Before starting the procedure all patients received thorough explanations and signed a written informed consent form prior to being enrolled in the trial. Pre-operative IOPA, Orthopantomogram (OPG) and CBCT provided the necessary information regarding the available bone and distance of vital structures, i.e., mandibular canal from the implant site, maxillary sinus, and floor of nasal cavity. The patients were pre-medicated with antibiotics (Amoxy-Clav-625 mg). Before anesthetizing the patient, the patients were asked to rinse the mouth with chlorhexidine mouth wash. Local anesthesia was then administered using lignocaine with adrenaline in the ratio of 1:100000 at the involved site. Surgical procedure was initiated with an intra-oral crestal incision and mucoperiosteal flaps elevated both buccally and lingually to expose the bone. After marking the site by custom made surgical stent, pilot drill was used, followed by subsequent drills of increasing diameter, and final drill up to the decided depth. The osteotomy site was irrigated copiously with normal saline. The implant was then inserted into this osteotomy site with the help of a torque wrench. Cover screws were then screwed to the implants immediately after implant placement to close the opened implant site. Similarly, the second osteotomy site in the same patient was irrigated copiously with Clindamycin (600mg/4ml)

followed by cover screw placement. The surgical site was thoroughly irrigated and flap was sutured using non-resorbable 3-0 silk sutures to achieve water-tight closure. The patients were prescribed with antibiotics and analgesics for 1 week, post-operatively. Patients were recalled after 24 hours for review and then after one week for assessment of post operative recovery, pain and suture removal surgeries. Patients were instructed to have a soft diet and to avoid chewing the treated area for first few days.

CLINICAL PARAMETERS:

- **Radiologic changes in crestal bone levels** in implants placed with clindamycin irrigation of osteotomy site and normal saline irrigation of osteotomy site.

The evaluation of crestal bone changes was done with help of radiographs.

The measurements were recorded at:

1. 1 months following implant placement
2. 2 month following dental implant placement
3. 3 month following dental implant placement

- **Patient’s perception of pain** Patients were asked to evaluate their pain experience at 1 week after surgery. Pain was assessed using a descriptive numerical rating scale of 0 to 10, with 0 indicative of no pain and 10 representing the worst pain imaginable. Patients were instructed that a score of

- 1 to 3 indicative of mild pain,
- 4 to 6 indicative of moderate pain
- 7 to 10 is indicative of severe pain.

- **Clinical peri-implant infection with or without suppuration.**

Assessed by: Present or Absent

All the results were analyzed by SPSS software.

RESULTS:

TABLE 1. Mean Crestal Bone Loss (Mesial) in two groups at different time intervals

VARIABLE	GROUP 1		GROUP 2		‘t’ value	p value
	MEAN	± SD	MEAN	± SD		
1 MONTHS	- 0.384	0.072	-0.246	0.065	4.47	0.00029
2 MONTHS	- 0.464	0.089	-0.323	0.078	3.74	0.00151
3 MONTHS	-0.597	0.066	-0.427	0.077	5.29	0.00005

TABLE 2. Mean Crestal Bone Loss (Distal) in two groups at different time intervals

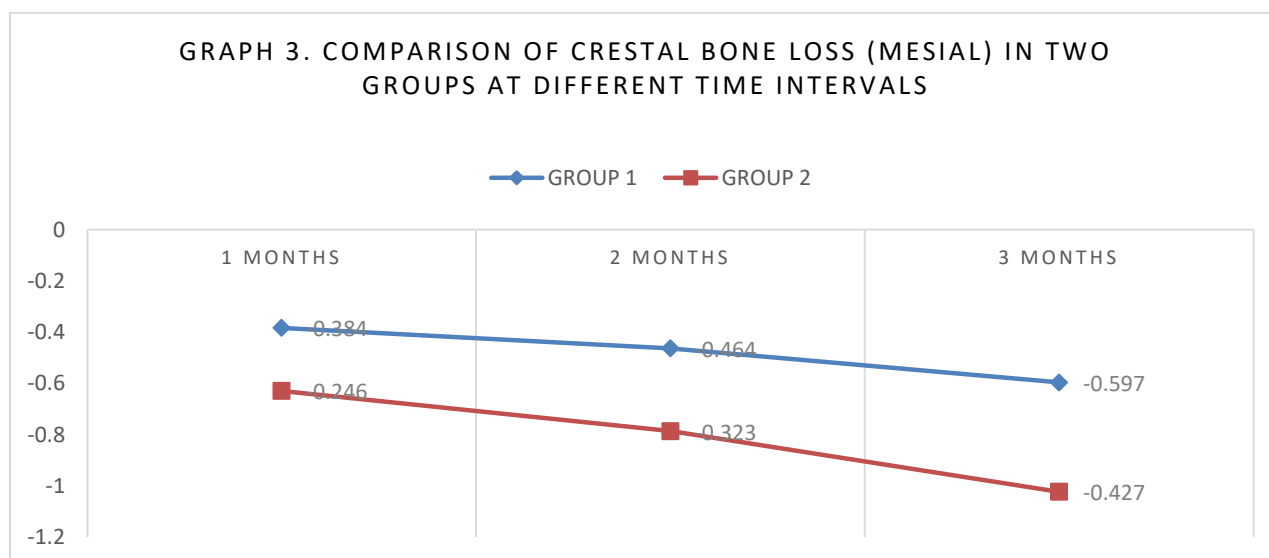
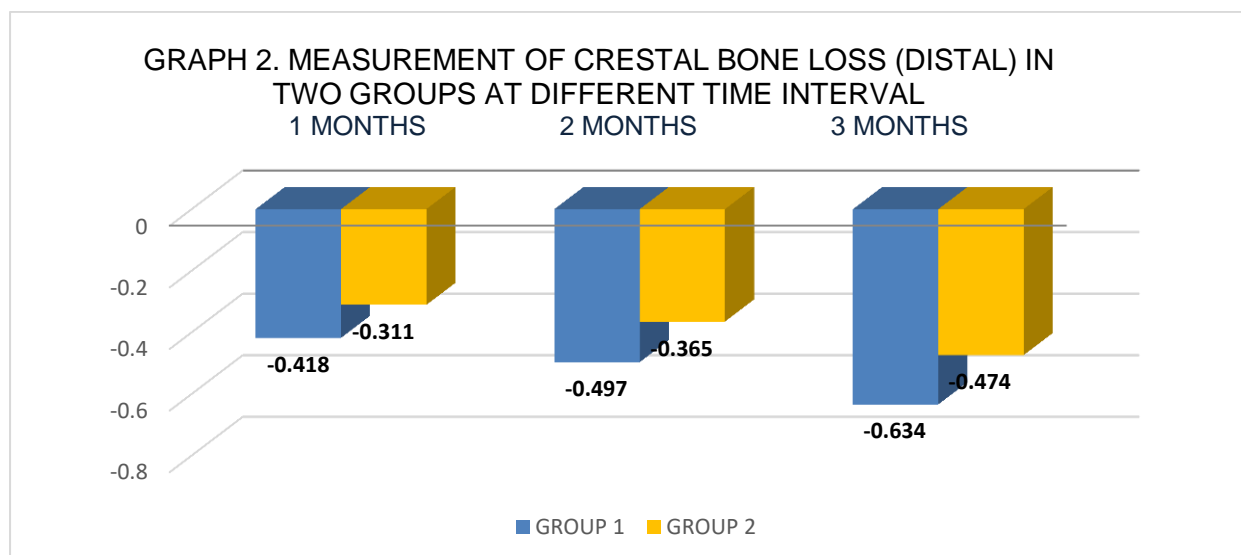
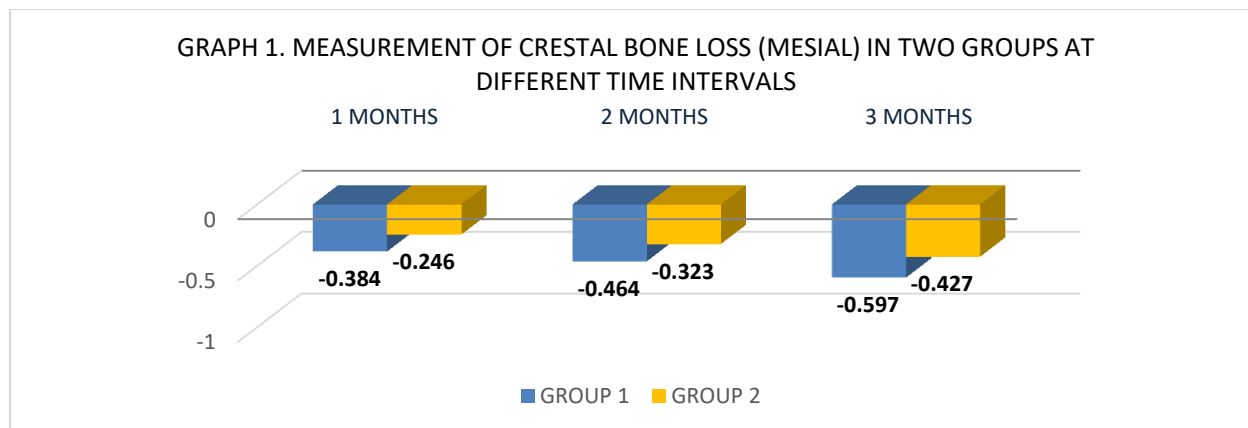
VARIABLE	GROUP 1		GROUP 2		‘t’ value	p value
	MEAN	± SD	MEAN	± SD		
1 MONTHS	-0.418	0.085	-0.311	0.069	3.07	0.00662
2 MONTHS	-0.497	0.077	-0.365	0.07	4.00	0.00083
3 MONTHS	-0.634	0.046	-0.474	0.056	6.91	0.00001

TABLE 3. Mean perception of pain in two groups

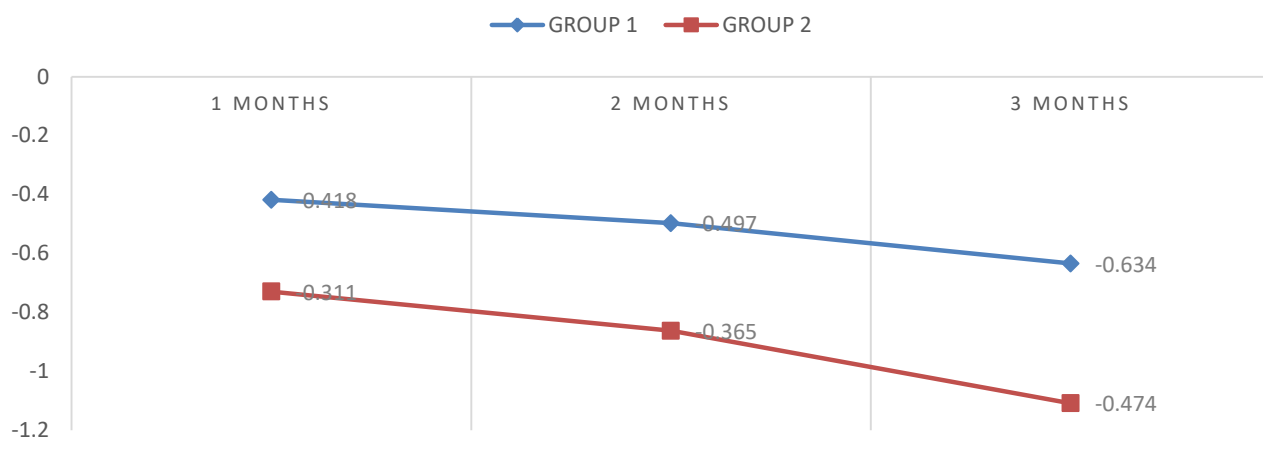
VARIABLE	GROUP 1		GROUP 2		‘t’ value	p value
	MEAN	± SD	MEAN	± SD		
Perception of pain	2.47	0.84	3.20	0.91	2.021	0.051

TABLE 4. Clinical peri-implant infection with or without suppuration

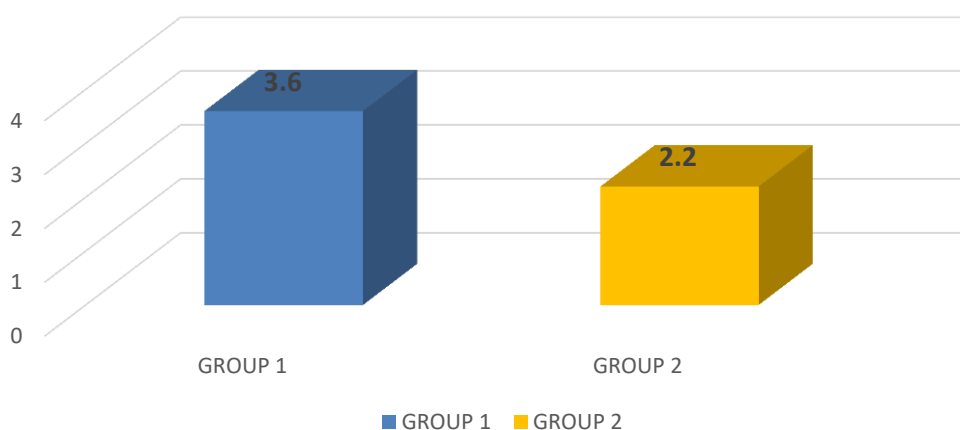
VARIABLE	GROUP 1		GROUP 2	
	N	%	N	%
Presence of clinical peri implant infection	2/10	20%	0/10	0%



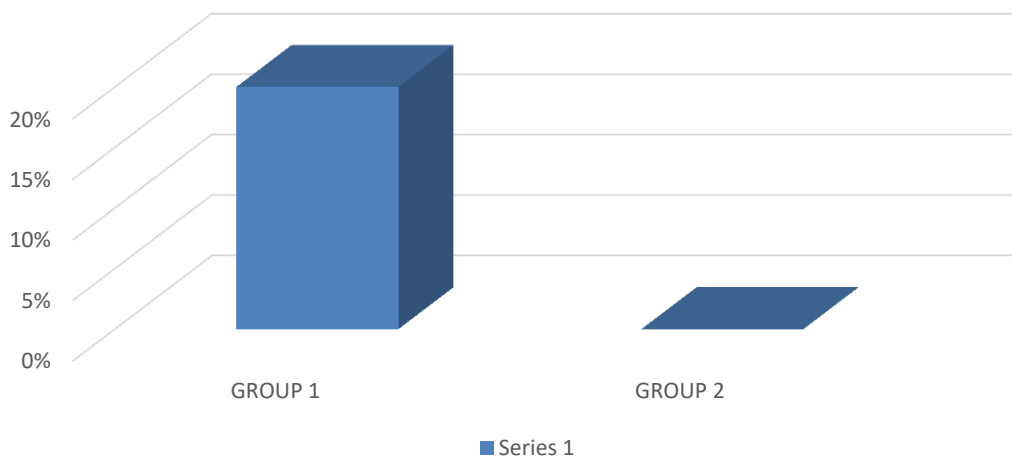
GRAPH 4. COMPARISON OF CRESTAL BONE LOSS (DISTAL) IN TWO GROUPS AT DIFFERENT TIME INTERVALS



GRAPH 5. MEASUREMENT OF PERCEPTION OF PAIN IN TWO GROUPS



GRAPH 6. COMPARISON OF CLINICAL PRESENCE OF PERI IMPLANT INFECTION WITH OR WITHOUT SUPPURATION OF THE TWO GROUPS



DISCUSSION

With the mouth being an inherently “dirty field”, with a multitude of flora, the incidence of bacteremia is also high. The aim always is to prevent the onset of infection in the surgical wound by achieving an antibiotic concentration in the area that will prevent bacterial proliferation and dissemination.⁽⁶⁾

Clindamycin is known to reach high concentrations in saliva, GCF, and bone. Several studies have shown that the concentration of clindamycin in these tissues is approximately 40% to 50% of the concentration in serum.⁽⁵⁾

The drug’s spectrum of antimicrobial activity along with the high concentrations achieved in bone indicate that clindamycin could be an effective agent in the management of implant-related infections.⁽⁷⁾

Present study aimed to compare the radiologic changes in peri-implant bone level in implants placed with normal saline and clindamycin irrigation for the two osteotomy sites. The mean of the mesial and distal crestal bone loss in sites irrigated with Normal Saline and Clindamycin at 1,2 and 3 months after implant placement was found to be significant (Table 1 and Table 2). The decrease in the marginal bone levels in sites irrigated by Clindamycin as compared to those with Normal saline can mainly be attributed to the fact that surgical wound irrigation reduces the bacterial load in a surgical or traumatic wound.⁽⁸⁾ Also it is supported by a study conducted on 17 patients by Hassan Mohajerani et al⁽⁹⁾, in which the autogenous particulate bone grafts were irrigated with clindamycin before placement and it was concluded that regardless of the time factor, all the microbial species population reduced after decontamination with clindamycin solution (20 µg/mL), except *Pseudomonas aeruginosa*. It was also concluded that low concentrations of clindamycin increased cell metabolism of human osteoblasts without significant changes in cell number. When comparing patient’s perception of pain perception levels with the procedure, the present study showed that the mean of the patient’s perception of pain for those irrigated with normal saline was 2.47 while the mean of the patient’s perception of pain for those irrigated with Clindamycin was 3.20. The p-value was 0.051 which is considered to be not significant (Table 3). Although insignificant, the patient’s perception of pain was lesser in those in which Clindamycin was used as the local irrigant. Decrease in perception of pain was supported by a study was conducted in total of 54 patients who applied to the clinic the first day after routine tooth extraction with severe pain in and around the extraction area which was irrigated with 4ml of sterile saline, rifampicin and clindamycin every 2 days. It was also found that clindamycin irrigation group had lower pain levels and alveolar mucosa healing was more effective. Clindamycin has

been reported to have very good bone invasion and biodegradability and that it can be used either alone or in combination for long periods in appropriate organisms.⁽¹⁰⁾

Present study also aimed to compare the peri-implant infections with or without suppuration. The study showed that 2 patients (20% of the total patients) in the Normal saline group showed peri implant infection with the presence of suppuration in the form of a sinus formation. While 0 patients showed such peri-implant infection in the Clindamycin group. (Table 4)

CONCLUSION:

It was observed that the mean pain levels of the patient with Normal Saline irrigation were greater than the pain levels of the patient with Clindamycin irrigation. It was also observed that crestal bone loss was lower in patients in whom implants were placed with Clindamycin as an irrigant for osteotomy site than in patients in whom implants were placed with Normal Saline as the irrigant accompanied with absence of any clinical peri-implant infection with or without suppuration in the group irrigated with Clindamycin. Within the limitations of this study it can be concluded that Clindamycin can be considered preferable over Normal Saline when placing and restoring dental implants.

REFERENCES

1. Resnik RR. Misch’s Contemporary Implant Dentistry. 4th edition, Elsevier.
2. Hemchand Surapaneni, Pallavi Samatha Yalamanchili, Md. Hafeez Basha, Sushma Potluri, Nirupa Elisetti, and M. V. Kiran Kumar Antibiotics in dental implants: A review of literature. *J Pharm Bioallied Sci.* 2016 Oct; 8(Suppl 1).
3. Marek Smieja. Current indications for the use of clindamycin: A critical review. *Can J Infect Dis.* 1998, Jan-Feb; 9(1): 22–28.
4. LeFrock JL, Molavi A, Prince RA. Clindamycin. *Med Clin North Am* 1982;66:103-20.
5. Brook I, Lewis MA, Sándor GK, Jeffcoat M, Samaranyake LP, Vera Rojas J. Clindamycin in dentistry: more than just effective prophylaxis for endocarditis? *Oral Surg Oral Med Oral Pathol Oral Radiol Endod.* 2005 Nov;100(5):550-8.
6. Khalil D. The use of antibiotic prophylaxis in implant dentistry a microbiological and clinical perspective thesis for doctoral degree (Ph.D.) 2017
7. Ahmad N, Saad N. Effects of antibiotics on dental implants: a review. *J Clin Med Res.* 2012;4(1):1-6.
8. Norman G, Atkinson RA, Smith TA, Rowlands C, Rithalia AD, Crosbie EJ, Dumville JC. Intracavity lavage and wound irrigation for prevention of surgical site infection. *Cochrane Database Syst Rev.* 2017 Oct 30;10(10):CD012234.
9. Mohajerani, H., Irajian, G., Latifi, F. et al. Efficacy of low-dose local clindamycin in different times for microbial decontamination of autogenous particulate bone graft. *Int J Implant Dent* 6, 70 (2020).
10. Çebi AT. Evaluation of the effects of intra-alveolar irrigation with clindamycin, rifampicin and sterile saline in alveolar osteitis treatment. *J Stomatol Oral Maxillofac Surg.* 2020 Jan 25:S2468-7855(20)30028-8