

## Original Research

### CLINICAL AND RADIOGRAPHIC EVALUATION IN CRESTAL AND SUBCRESTAL IMPLANT PLACEMENT- A PROSPECTIVE ORIGINAL STUDY

Renu Gupta<sup>1</sup>, Priyanka Singh<sup>2</sup>, Divya Vashisth<sup>3</sup>, Bhavya Aggarwal<sup>4</sup>, Vijay Chib<sup>2</sup>, Niyati Arora<sup>2</sup>

<sup>1</sup>Professor & Head, <sup>2</sup>PG Student, <sup>3</sup>Profefssor, Department of Prosthodontics, HPGDC, Shimla (HP)

<sup>4</sup>MBBS Final year student, GMCH Amritsar

#### ABSTRACT:

**Background-**The long-term survival of dental implants is evaluated by the amount of crestal bone loss around the implants. Many possible etiologies of early crestal bone loss around implants including surgical trauma, occlusal overload, periimplantitis, the presence of microgap, reformation of biologic width, implant crest module, and others have been proposed. However, the location of dental implants, whether subcrestal or equicrestal, is still becoming increasing importance for researchers. **Materials and Method-** A total of 20 implants were placed (10 dental implants per group, group I-Equicrestal and Group II- 1mm Subcrestal) in subjects requiring placement of mandibular teeth. Patient was then recalled for follow up for radiographic evaluation which was made at 1 month and 3 months of implant loading for evaluation of crestal bone changes with the help of radiographs. **Result-** The results says that crestal bone loss around implants which are placed equicrestal led to lesser bone loss when compared to implants which are placed subcrestal after loading and patient's perception of pain was lesser in the equicrestal implants as compared to subcrestal implants.

Key words: Crestal, Implant

Received: March 02, 2021

Accepted: April 05, 2021

**Corresponding Author:** Dr. Priyanka Singh, PG Student, Department of Prosthodontics, HPGDC, Shimla (HP)

**This article may be cited as:** Gupta R, Singh P, Vashisth D, Aggarwal B, Chib V, Arora N. Clinical and radiographic evaluation in crestal and subcrestal implant placement- A prospective original study. Int J Res Health Allied Sci 2021;7(2):100- 105

#### INTRODUCTION

*"Dental implants have emerged as a panacea for the treatment of edentulism, both partial and complete".*

Dental implants have become a standardized and predictable treatment modality for the rehabilitation of partially and totally edentulous patients, resulting in high survival and success rates.<sup>[2]</sup> Several factors may contribute to the success or failure of a dental implant, including bone support and the stability of the bone crest adjacent to the implant.

A zone of epithelium and connective tissue integration forms a "biologic width" that surrounds and protects an abutment and implant from pathologic insults. It has been observed that if the biologic width is altered in an apical direction, a corresponding marginal bone loss will also occur. This area of bone loss usually starts at the implant-abutment interface.<sup>[1]</sup> The long-term survival of dental implants is evaluated by the

amount of crestal bone loss around the implants. This peri implant crestal bone level and peri implant bone remodelling depends upon location of Implant Abutment Junction (IAJ) in relation to bone crest and the amount of soft tissue coverage<sup>[3]</sup>. Many possible etiologies of early crestal bone loss around implants (from implant placement to 1-year post-loading) including surgical trauma, occlusal overload, periimplantitis, the presence of microgap, reformation of biologic width, implant crest module, and others have been proposed. However, the location of dental implants, whether subcrestal or equicrestal, is still becoming increasing importance for researchers.<sup>[6]</sup> Hence, the aim of this in -vivo study is to evaluate the impact of crestal and subcrestal implant placement in clinico-radiological parameters such as crestal bone

loss, clinical attachment level and patients perception of pain.

## MATERIALS AND METHODS

The study was conducted on subjects visiting the Department of Prosthodontics and Crown & Bridge, Himachal Pradesh Government Dental College and Hospital, Shimla. The ethical approval by the Institute Ethical Committee was obtained. The subjects were evaluated based on clinical and radiographic parameters for implant placement by two techniques (crestal and subcrestal).

### Study population:

The study included statistically significant patients in which minimum of two implants were placed in edentulous region having adequate amount of bone and keratinized tissue.

### The selection criteria was as follows:

#### Inclusion criteria

- All patients requiring minimum two dental implants.
- Adequate amount of bone and keratinized tissue.
- All subjects should be 18 or greater than 18 years of age.
- All patients should be periodontally healthy.

#### Exclusion criteria

- Irradiation in the head and neck area less than 1 year
- Poor oral hygiene and motivation
- Untreated periodontal disease
- Systemic contraindications such as Uncontrolled Diabetes etc.
- Active infection or severe inflammation in the area.

### Study Groups

A total of 20 implants were placed (10 dental implants per group) in subjects requiring placement of mandibular teeth. Selected subjects were grouped on the basis of type of surgery during implant placement as:

**Group I:** implant placed equicrestal

**Group II:** implants placed 1 mm subcrestal

**Randomization:** Randomization of study subjects was done by lottery method. Each subject was told to randomly choose from identical slips for different groups.

## METHODOLOGY

### 1. Presurgical Assessment:

- A detailed medical and dental history of each subject was obtained along with preoperative photographs and radiographs.
- Pre-operative IOPA and Orthopantomogram (OPG) provided the necessary information regarding the available bone and distance of vital structures, i.e., mandibular canal from the implant site, maxillary sinus, and floor of nasal cavity. A pre-measured 3mm diameter ball bearing was used to calculate the magnification of OPG.

- CBCT was used to accurately evaluate the amount of bone and proximity from vital structures for each patient.

- All subjects were motivated to maintain oral hygiene.

### 2. Fabrication of Study Models and Surgical Stent:

Preliminary alginate impressions were made and study models fabricated prior to surgery. A diagnostic wax-up of the involved tooth was made and a surgical stent was fabricated based on the wax-up to facilitate implant placement.

### 3. Surgical Preparation:

The patients were pre-medicated with antibiotics (Amoxicillin 2g) 1 hour prior to surgery and were asked to rinse the mouth with Chlorhexidine 0.2% . Local anaesthesia was administered using Lignocaine with adrenaline in the ratio of 1:100000 at the involved site.

### 4. Surgical Procedure:

#### ➤ Implant Placement Procedure:

- Crestal incision was given for full thickness flap reflection, mucoperiosteal flap was elevated both buccally and lingually to expose the bone.
- Surgical stent was then placed over the crest to mark the implant site. The implant diameter was kept the same while placing implants equicrestal and subcrestal.
- The implant site was penetrated with the help of a pilot drill which was used to create a bleeding point at site of initial osteotomy when the surgical stent was still in place.
- After marking the implant site by surgical stent, the surgical stent was removed and pilot drill was used to complete depth, followed by subsequent drills of increasing diameter to create an osteotomy site of required dimensions for each patient.
- A paralleling pin was used during osteotomy preparation to assess the drilling orientation.
- Implant was placed equicrestal into this osteotomy site with the help of a torque wrench.
- Healing abutments (Gingival formers) / cover screw was then screwed to the implants immediately after implant placement to close the opened implant site.
- Once the healing abutments were placed the surgical site was thoroughly irrigated and flap was sutured using non-resorbable 3-0 silk sutures to achieve water-tight closure.
- Similarly, Group II Implants were placed 1 mm subcrestally.
- Patients were prescribed with antibiotics and analgesics for 1 week, post-operatively.

### 5. Medication and Follow up-

Post-operative instructions were given to the patients regarding diet, oral hygiene maintenance and following medications were prescribed:

Patients were instructed to have a soft diet and to avoid chewing the treated area for first few days. Oral

hygiene at the surgical site was limited to soft brushing for the first 2 weeks and regular brushing in the rest of the mouth.

After implant placement by both the techniques implants were left for osseointegration for a period of 3 months following conventional loading protocols and abutments were placed thereafter.

**RESULTS**

**TABLE 1.- Mean Crestal Bone Loss (Mesial) in two groups at different time intervals**

| Variable     | Group I |       | Group II |       | t' value | p value |
|--------------|---------|-------|----------|-------|----------|---------|
|              | Mean    | ± SD  | Mean     | ± SD  |          |         |
| At 0th Month | -0.309  | 0.054 | -0.422   | 0.120 | 2.71     | 0.01444 |
| At 1st Month | -0.385  | 0.062 | -0.576   | 0.101 | 5.07     | 0.00008 |
| At 3rd month | -0.487  | 0.062 | -0.703   | 0.078 | 6.80     | 0.00001 |

**TABLE 2.- Mean Crestal Bone Loss (Distal) in two groups at different time intervals**

| Variable     | Group I |       | Group II |       | t' value | p value |
|--------------|---------|-------|----------|-------|----------|---------|
|              | Mean    | ± SD  | Mean     | ± SD  |          |         |
| At 0th Month | -0.262  | 0.077 | -0.402   | 0.082 | 3.93     | 0.00098 |
| At 1st Month | -0.310  | 0.085 | -0.565   | 0.071 | 7.23     | 0.00001 |
| At 3rd month | -0.581  | 0.047 | -0.681   | 0.062 | 4.02     | 0.00081 |

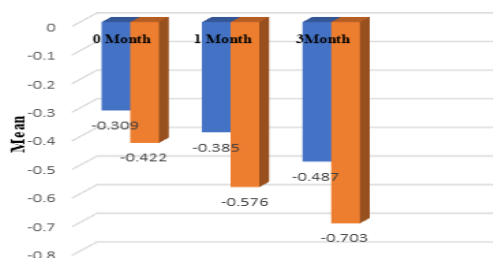
**TABLE 3 Mean of clinical attachment loss at different time intervals of Group I and II implants.**

| Variable     | Group I |      | Group II |      | t' value | p value |
|--------------|---------|------|----------|------|----------|---------|
|              | Mean    | ± SD | Mean     | ± SD |          |         |
| At 0th Month | -       | -    | -        | -    | -        | -       |
| At 1st Month | 1.35    | 0.47 | 1.40     | 0.45 | 0.239    | 0.813   |
| At 3rd month | 1.50    | 0.40 | 1.65     | 0.41 | 0.818    | 0.423   |

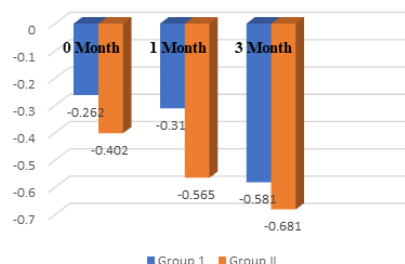
**TABLE-4: Mean Perception of Pain in Two Groups**

| Variable           | Group 1 |      | Group 2 |      | t' value | p value |
|--------------------|---------|------|---------|------|----------|---------|
|                    | Mean    | ± SD | Mean    | ± SD |          |         |
| Perception of Pain | 2.47    | 0.84 | 3.20    | 0.91 | 2.028    | 0.059   |

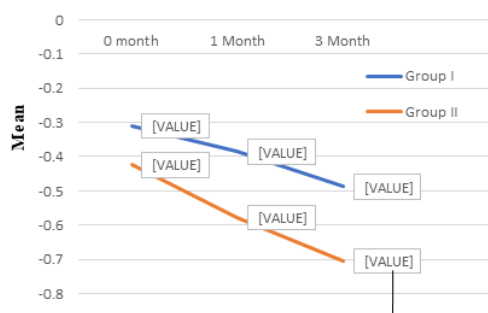
**Graph 1. Comparison of crestal bone loss (in mesial) in two groups at different time intervals**



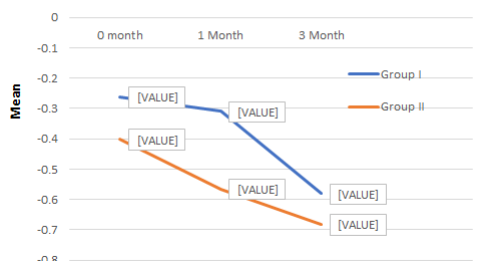**Graph 2. Comparison of crestal bone loss (in distal) in two groups at different time intervals**



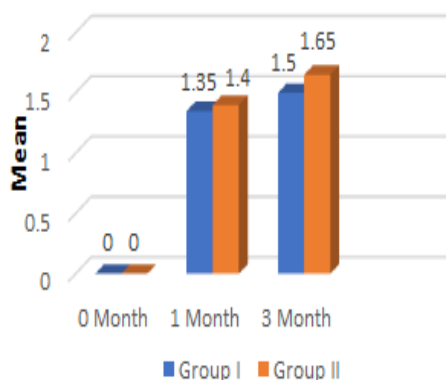
**Graph 3. Intragroup change in crestal bone loss (mesial) at different time intervals**



**Graph 4. Intragroup change in crestal bone loss (distal) at different time intervals**



**Graph 5. Clinical attachment level at different time intervals**



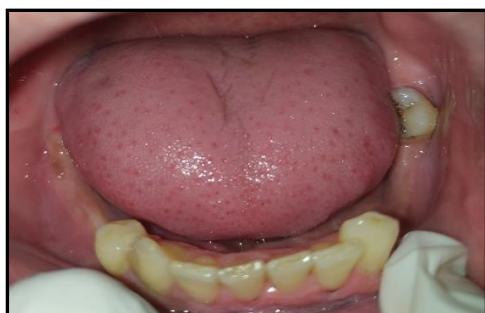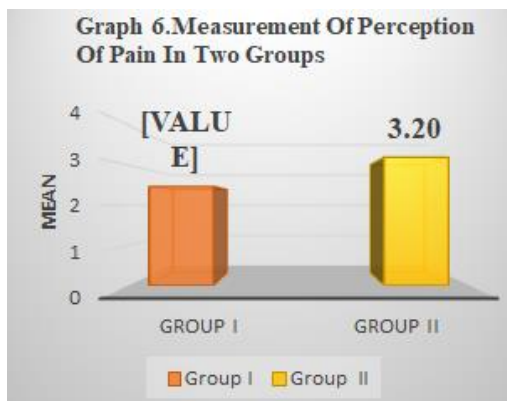


Fig.1: Pre-Operative Intra-Oral View

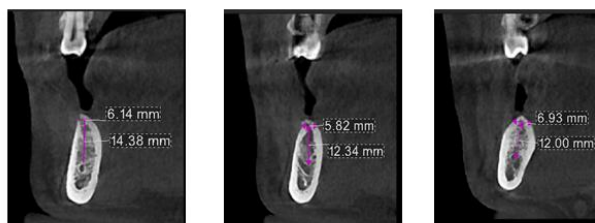


Fig. 2: PRE-OPERATIVE CBCT

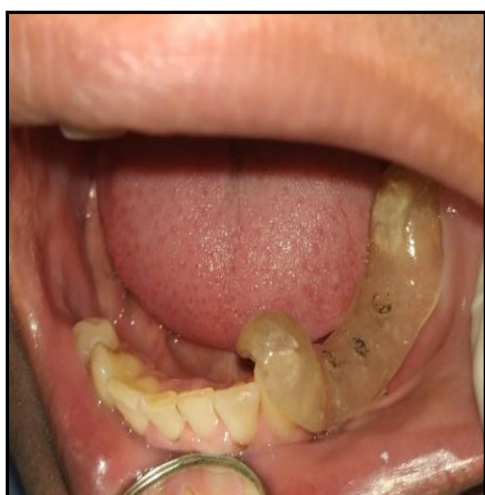

Fig. 3: Marking With Surgical Stent

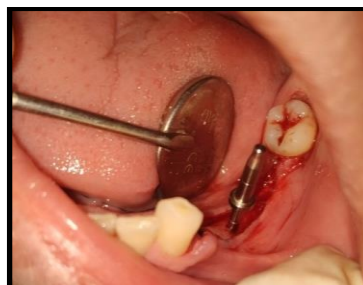


Fig.4: Paralleling Pin Placed For 1<sup>st</sup>(Subcrestal) Implant

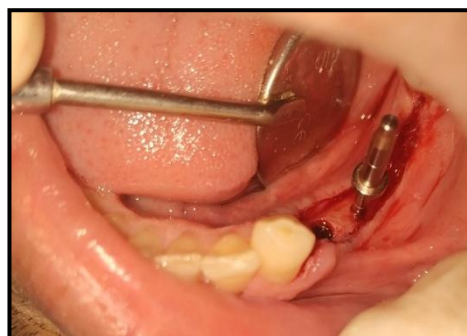

Fig. 5 : Subcrestal Placement Of 1<sup>st</sup> Implant and Paralleling Pin Placed For 2<sup>nd</sup> (Equicrestal) Implant

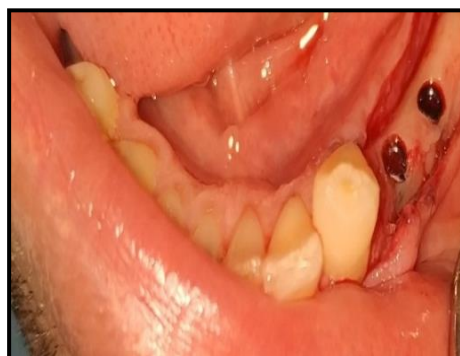

Fig. 6: Placement Of All Implants

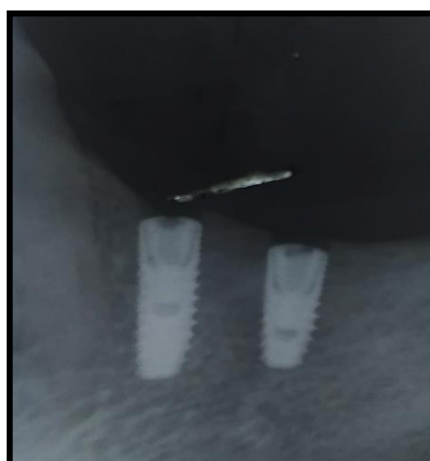
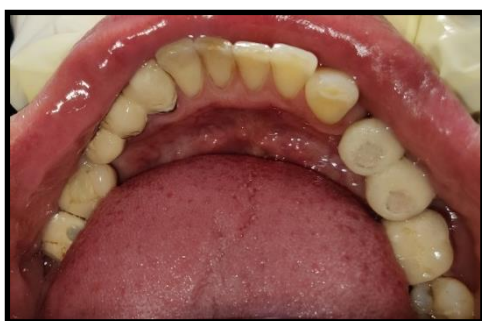

Fig.7: Post-Operative IOPA Of Subcrestal And Equicrestal Implant Placement



**Fig. 8: Final Prosthesis Placed**

## CONCLUSION

It was observed that among the parameters considered to compare both the loading protocol the crestal bone loss around the implant after 3 months follow up shows significant difference. The result says that crestal bone loss around implants which are placed equicrestal led to lesser bone loss when compared to implants which are placed subcrestal after loading , considering all the other factors remains unchanged .It was also observed that patient's perception of pain was lesser in the equicrestal implants as compared to subcrestal implants. Within the limitations of this study, it can be concluded that equicrestal implant placement might be preferable over subcrestal implant placement restoring dental implants.

Further observational and randomized controlled studies with a longer follow-up could provide deeper evidence-based conclusions concerning the use of narrow diameter implants.

## REFERENCES

1. Fetner M, Fetner A, Koutouzis T, Clozza E, Tovar N, Sarendranath A, Coelho PG, Neiva K, Janal MN, Neiva R. The Effects of Subcrestal Implant Placement on Crestal Bone Levels and Bone-to-Abutment Contact: A Microcomputed Tomographic and Histologic Study in Dogs. *Int J Oral Maxillofac Implants*. 2015 Sep-Oct;30(5):1068-75
2. CristinaValles ,XavierRodríguez-Ciurana ,Marco Clementini , Mariana Baglivo , Blanca Paniagua , JoseNart-Influence of subcrestal implant placement compared with equicrestal position on the peri-implant hard and soft tissues around platform-switched implants: a systematic review and meta-analysis. *Clin Oral Invest* 22, 555–570 (2018).
3. Koutouzis T, Fetner M, Fetner A, Lundgren T. Retrospective evaluation of crestal bone changes around implants with reduced abutment diameter placed non-submerged and at subcrestal positions: the effect of bone grafting at implant placement. *J Periodontol*. 2011 Feb;82(2):234-42
4. Arthur B. Novaes, Raquel R. M. Barros, Valdir A. Muglia, Germana J. Borges-Influence of inter implant distances and Placement depth on papilla formation and Crestal resorption: A clinical and Radiographic study in dogs. *Journal of Oral Implantology*. Vol. XXXV/No. One/2009.
5. Hilario Pellicer-Chover, María Peñarrocha-Diago, David Peñarrocha-Oltra, Sonia Gomar-Vercher,Rubén Agustín-Panadero, and Miguel Peñarrocha-Diago. Impact of crestal and subcrestal implant placement in peri-implant bone. *Med Oral Patol Oral Cir Bucal*.2016 Jan 1;21(1):e103-10.
6. Aous Dannan. Crestal Bone Loss Around Dental Implants; A Short Communication. *The Internet Journal of Dental Science*. 2012 Volume 10 Number 2
7. Hermann, J. S., Buser, D., Schenk, R. K., & Cochran, D. L. (2000). Crestal Bone Changes Around Titanium Implants. A Histometric Evaluation of Unloaded Non-Submerged and Submerged Implants in the Canine Mandible. *Journal of Periodontology*, 71(9), 1412–1424.
8. Hämmerle CH, Brägger U, Bürgin, Lang NP.- The effect of subcrestal placement of the polished surface of ITI implants on marginal soft and hard tissues. *Clin Oral Implants Res*. 1996 Jun;7(2):111-9.
9. Leonhardt Å, Gröndahl K, Bergström C, Lekholm U. Long-term follow-up of osseointegrated titanium implants using clinical, radiographic and microbiological parameters. *Clin. Oral Impl. Res*, 13, 2002; 127–132.
10. Tomas Linkevicius, Dr Habil, Simonas Grybauskas.The Influence of Soft Tissue Thickness on Crestal Bone Changes Around Implants: A 1-Year Prospective Controlled Clinical Trial. *Int J Oral Maxillofac Implants* 2009;24:712–719.
11. Welander M, Abrahamsson I, Berglundh T. Subcrestal placement of two-part implants. *Clin. Oral Impl. Res*. 20, 2009; 226–231.
12. Donovan R, Fetner A, Koutouzis T, Lundgren T. Crestal bone changes around implants with reduced abutment diameter placed non-submerged and at subcrestal positions: a 1-year radiographic evaluation. *J Periodontol*. 2010 Mar;81(3):428-34
13. Koh RU, Oh TJ, Rudek I, Neiva GF, Misch CE, Rothman ED, Wang HL. Hard and soft tissue changes after crestal and subcrestal immediate implant placement. *J Periodontol*. 2011 Aug;82(8):1112-20
14. Marco Degidi, Vittoria Perrotti, Jamil A. Shibli, Arthur B. Novaes, Adriano Piattelli, and Giovanna Iezzi. Equicrestal and Subcrestal Dental Implants: A Histologic and Histomorphometric Evaluation of Nine Retrieved Human Implants. *J Periodontol* 2011;82:708-715.
15. Romanos, G. E., Aydin, E., Gaertner, K., & Nentwig, G.-H. (2013). Long-Term Results after Subcrestal or Crestal Placement of Delayed Loaded Implants. *Clinical Implant Dentistry and Related Research*, 17(1), 133–141.
16. Lombardo G,Corrocher G,Pighi J, Faccioni F, Rovera A, Marincola M, Nocini PF.The impact of subcrestal placement on short locking-taper implants placed in posterior maxilla and mandible: a retrospective evaluation on hard and soft tissues stability after 2 years of loading. *Minerva Stomatol*. 2014 Nov-Dec;63(11-12):391-402.
17. Calvo-Guirado JL, Lopez-Lopez PJ, Mate Sanchez JE, Gargallo Albiol J, Velasco Ortega E, Delgado Ruiz R. Crestal bone loss related to immediate implants in crestal and subcrestal position: a pilot study in dogs. *Clin. Oral Impl. Res*. 25, 2014, 1286–1294.
18. Lee, J., Fiorini, T., Gamborena, I., Wenzel, B. A., Schüpbach, P., Wikesjö, U. M. E., & Susin, C. Effect of Platform Shift/Switch on Crestal Bone Levels and Mucosal Profile Following Flapless Surgery and Crestal/Subcrestal Implant Placement. *Clinical Implant Dentistry and Related Research*, 18(1), 73–81
19. Kütan, E., Bolukbasi, N., Yildirim-Ondur, E., & Ozdemir, T. Clinical and Radiographic Evaluation of

- Marginal Bone Changes around Platform-Switching Implants Placed in Crestal or Subcrestal Positions: A Randomized Controlled Clinical Trial. *Clinical Implant Dentistry and Related Research*, 17, e364–e375.
20. Palaska I, Tsaousoglou P, Vouros I, Konstantinidis A, Menexes G. Influence of placement depth and abutment connection pattern on bone remodeling around 1-stage implants: a prospective randomized controlled clinical trial. *Clin. Oral Impl. Res.* 00, 2014, 1–10.
  21. Balaji Nagarajan, Varsha Murthy, David Livingstone, Manohar Paul Surendra, and Srinivasan Jayaraman Evaluation of Crestal Bone Loss Around Implants Placed at Equicrestal and Subcrestal Levels Before Loading: A Prospective Clinical Study. *J Clin Diagn Res.* 2015 Dec; 9(12): ZC47–ZC50.
  22. Aimetti M, Ferrarotti F, Mariani GM, Ghelardoni C, Romano F. -Soft tissue and crestal bone changes around implants with platform-switched abutments placed nonsubmerged at subcrestal position: a 2-year clinical and radiographic evaluation. *Clin Oral Implants Res.* 2017 Nov;28(11):1342-134
  23. Van Eekeren, P., Tahmaseb, A., & Wismeijer, D. Crestal Bone Changes Around Implants with Implant-Abutment Connections at Epicrestal Level or Above: Systematic Review and Meta-Analysis. *The International Journal of Oral & Maxillofacial Implants*, 31(1), 119–124.
  24. Al Amri, M. D. Crestal bone loss around submerged and nonsubmerged dental implants: A systematic review. *The Journal of Prosthetic Dentistry*, 115(5), 564–570.e1.
  25. De Siqueira RAC, Fontão FNGK, Sartori IAM, Santos PGF, Bernardes SR, Tioffi R. Effect of different implant placement depths on crestal bone levels and soft tissue behavior: a randomized clinical trial. *Clin Oral Implants Res.* 2017 Oct;28(10):1227-1233
  26. Gatti, C., Gatti, F., Silvestri, M., Mintrone, F., Rossi, R., Tridondani, G., Borrelli, P. A Prospective Multicenter Study on Radiographic Crestal Bone Changes Around Dental Implants Placed at Crestal or Subcrestal Level: One-Year Findings. *The International Journal of Oral & Maxillofacial Implants*, 33(4), 913–918.
  27. Natalia Palacios-Garzón, Eugenio Velasco-Ortega, José López-López- Bone Loss in Implants Placed at Subcrestal and Crestal Level: A Systematic Review and Meta-Analysis. *Publisher of Open Access Journals. Materials* 2019, 12, 154.
  28. Al Amri, M.D.; Alfadda, S.A.; Labban, N.Y.; Alasqah, M.N.; Alshehri, F.A.; Al-Rasheed, A.S. Comparison of Clinical, Radiographic, and Immunologic Inflammatory Parameters around Crestally and Subcrestally Placed Dental Implants: 5-Year Retrospective Results. *J. Prosthodont.* 2017.
  29. Calvo-Guirado, J. L., Pérez-Albacete, C., Aguilar-Salvatierra, A., de Val Maté-Sánchez, J. E., Delgado-Ruiz, R. A., Abboud, M., Romanos, G. E. Narrow-versus mini-implants at crestal and subcrestal bone levels. Experimental study in beagle dogs at three months. *Clinical Oral Investigations*, 19(6), 1363–1369.
  30. Degidi, M., Perrotti, V., Shibli, J. A., Novaes, A. B., Piattelli, A., & Iezzi, G. Equicrestal and Subcrestal Dental Implants: A Histologic and Histomorphometric Evaluation of Nine Retrieved Human Implants. *Journal of Periodontology*, 82(5), 708–715.