

# International Journal of Research in Health and Allied Sciences

Journal home page: [www.ijrhas.com](http://www.ijrhas.com)

Official Publication of "Society for Scientific Research and Studies" [Regd.]

ISSN: 2455-7803

## Review Article

### Regenerative endodontics procedure and material in adult: A systematic review

Bushra Shoab<sup>1</sup>, Wejdan Melfi Alotaibi<sup>2</sup>, Shatha Mansour Alotaibi<sup>3</sup>, Alaa Mohammad Alnukta<sup>4</sup>, Layla Othman Albalbisi<sup>5</sup>, Eshraq Zaki Abuamer<sup>6</sup>

<sup>1</sup>Lecturer, Restorative Department, Riyadh Elm University, Riyadh, Kingdom of Saudi Arabia;

<sup>2,3,4,5,6</sup>Dental student, Riyadh Elm University, Riyadh, Kingdom of Saudi Arabia

#### ABSTRACT:

**Aim:** The aim of this study was to review available literature to evaluate procedure and material for regenerative endodontics.

**Materials and Methods:** In this systematic review 27 articles were selected to review procedure and material for endodontics regenerative.

**Results:** Most of the studies showed current endodontic therapy depends on the idea that disinfected root canals should be sealed with as little residual space as possible to limit bacterial recolonization. MTA was placed over the coagulated blood clot and a cotton pellet and glass ionomer cement was utilized to seal the access cavity. 2.5-3% sodium hypochlorite and saline followed by evoked bleeding and MTA sealing over the blood clot with intermediate restorative material. **Conclusions:** Regenerative endodontic treatment is based on the concept of tissue engineering technology to regenerate the dentine-pulp complex in the canal space of immature permanent teeth damaged by caries or trauma.

**Key words:** Regenerative endodontic treatment, procedure, materials

Received: 24 October, 2019

Revised: 29 December, 2019

Accepted: 30 December, 2019

**Corresponding author:** Bushra Shoab, Lecturer, Restorative Department, Riyadh Elm University, Riyadh, Kingdom of Saudi Arabia

**This article may be cited as:** Shoab B , Alotaibi WM, Alotaibi SM, Alnukta AM, Albalbisi LO, Abuamer EZ. Regenerative endodontics procedure and material in adult: A systematic review. Int J Res Health Allied Sci 2020;6(1):1-5.

#### INTRODUCTION

The history of endodontic regenerative processes first approaches to dental pulp regeneration date back to the 1960s when Ostby assessed the function of the blood clot in endodontic therapy.<sup>1</sup> He performed pre-clinical and clinical tissue regeneration research in both dogs and patients, where he caused bleeding to the apical part of the root canal, followed by filling the two-thirds of the coronal with gutta-percha and Kloroperka paste. He noted a gradual replacement of the blood clot in the channel with granulation tissue and fibrous connective tissue, but tissue formation stayed incomplete and did not fill the entire root canal. Regenerative endodontic therapy (RET) is a new approach for teeth with necrotic

pulp and immature roots defined as "biologically based procedures to replace damaged structures, including dentin and root structures, as well as cells of the pulp-dentin complex."<sup>2</sup> In the treatment of immature teeth, it can result in continued root maturation and apical closure by calcium hydroxide apexification and apical barrier techniques with mineral trioxide aggregate (MTA).<sup>3</sup> It has been used in the treatment of immature teeth with pulp necrosis though generally there is no further root development, so the roots remain thin and fragile with a higher risk of fracture and tooth loss.<sup>2</sup>

A prevalent complication involving the removal or extraction of the tooth is repopulation of the root canal system with microorganisms due to residual bacteria in

inaccessible fields or due to permeable root fillings or coronary restoration.<sup>4</sup> The formation of caries is another cause of subsequent extraction of teeth with root fillings. So, the existence of an essential pulp could provide biological defense mechanisms such as maintenance of interstitial pulp stress.<sup>5</sup> The most satisfactory treatment technique for teeth with infected or non-infected necrotic pulp that disinfected root canal space should be loaded with biocompatible material to prevent reinfection of the canal space for a long time. The essential objective of the regenerative procedure is elimination of clinical manifestation signs and resolution of apical periodontitis.

The procedure of regenerative endodontic treatment is to include antibiotic that will disinfect of the root canal. Multiple types of aerobic and anaerobic bacteria cause infection of the root canals, and henceforth it is hard to disinfect the canals successfully with just one type of antibiotic. Therefore, Hoshino et al. prescribed mix of three antibiotics including ciprofloxacin, metronidazole, and minocycline called Triple antibiotic paste (TAP).<sup>6</sup> MTA present an antimicrobial impact against certain microorganism. Not changing the intracanal medication may promote a similar result but along time with a higher risk of infection. This procedure presents some disadvantages, such as the patient needs to attend multiple times and it's a long treatment, taking between 6 to 24 months to complete (Table). However, when compared between the traditional and regenerative protocols we will see that revascularization was associated with significantly greater increase in root length and thickness compared with calcium hydroxide apexification and MTA barrier placement as well as higher overall survival rates.

## MATERIALS AND METHODS

This is a comparative study of 27 articles that had been reviewed from three international databases (PubMed, PMC, and Medline) after applying exclusion and inclusion criteria using the following keywords: Regenerative endodontic treatment, procedure, adult, and materials. Inclusion and exclusion criteria: Articles that studied regenerative endodontics procedure and material in adult were included. All cross-sectional and randomized controlled in vitro studies were included. Case reports, studies on primary teeth, and articles with questionable sources were excluded.

## RESULTS

Following PRISMA statement (Figure), 27 articles were identified as relevant to the topic, duplicated articles were excluded resulting in paper 6, out of which 27 relevant after screening titles and abstract, 27 evidence paper met inclusion criteria for qualitative synthesis. Two articles reported selection cases for regenerative endodontic is pulp necrosis, immature apices, pulp

space no need for post and core, apical periodontitis. Thirteen articles reported about calcium hydroxide and triple antibiotic paste are the most used as intracanal medicament. Five articles reported TAP can resistance against bacteria, cause discoloration, allergic reaction. Three articles show TAP concentration used about (100 mg)

Fourteen articles observed about Sodium hypochlorite 1.5-5.25% (20 ml) has been utilized as irrigation and disinfection for regenerative endodontic treatment with 17% of EDTA improved to survive SCAP and seven articles showed EDTA has been utilized as final rinse each appointment to survived both stem cell and growth factors. Three articles showed calcium hydroxide cause staining, fracture of immature teeth. Five articles showed calcium hydroxide has high pH leading to death of SCAP. Three articles reported the utilization of chlorhexidine will inhibit stem cell differentiation and no longer employed. Three articles showed MTA can cause discoloration when placed on the top of blood clot.

Six articles reported the current endodontic therapy depends on the idea that disinfected root canals should be sealed with as little residual space as possible to limit bacterial recolonization, MTA was placed over the coagulated blood clot and a cotton pellet and glass ionomer cement was utilized to seal the access cavity and 3-2.5% sodium hypochlorite and saline followed by evoked bleeding and MTA sealing over the blood clot with intermediate restorative material. Four articles reported follow up must be in 3, 6, 12, 18, and 24 months in next years.

## DISCUSSION

In general, the regenerative endodontic treatments reviewed could be considered clinically successful. However, the histological analysis of the newly formed tissue has been identified to encourage canal wall thickening and/or continued root growth.<sup>7, 8</sup> The most encouraging results with the use of dental pulp stem cells seeded into scaffolds and enables the growth factor to remain in contact with these cells. Disinfection depends almost exclusively on irrigants and intracanal medication, sodium hypochloride.<sup>9, 10</sup> 1.5-5.25% (20 ml) used as irrigation followed by 17% of EDTA to improve and survive SCAP promote the release of the growth factor and expose the collagen fibers in dentin.<sup>11, 12</sup>

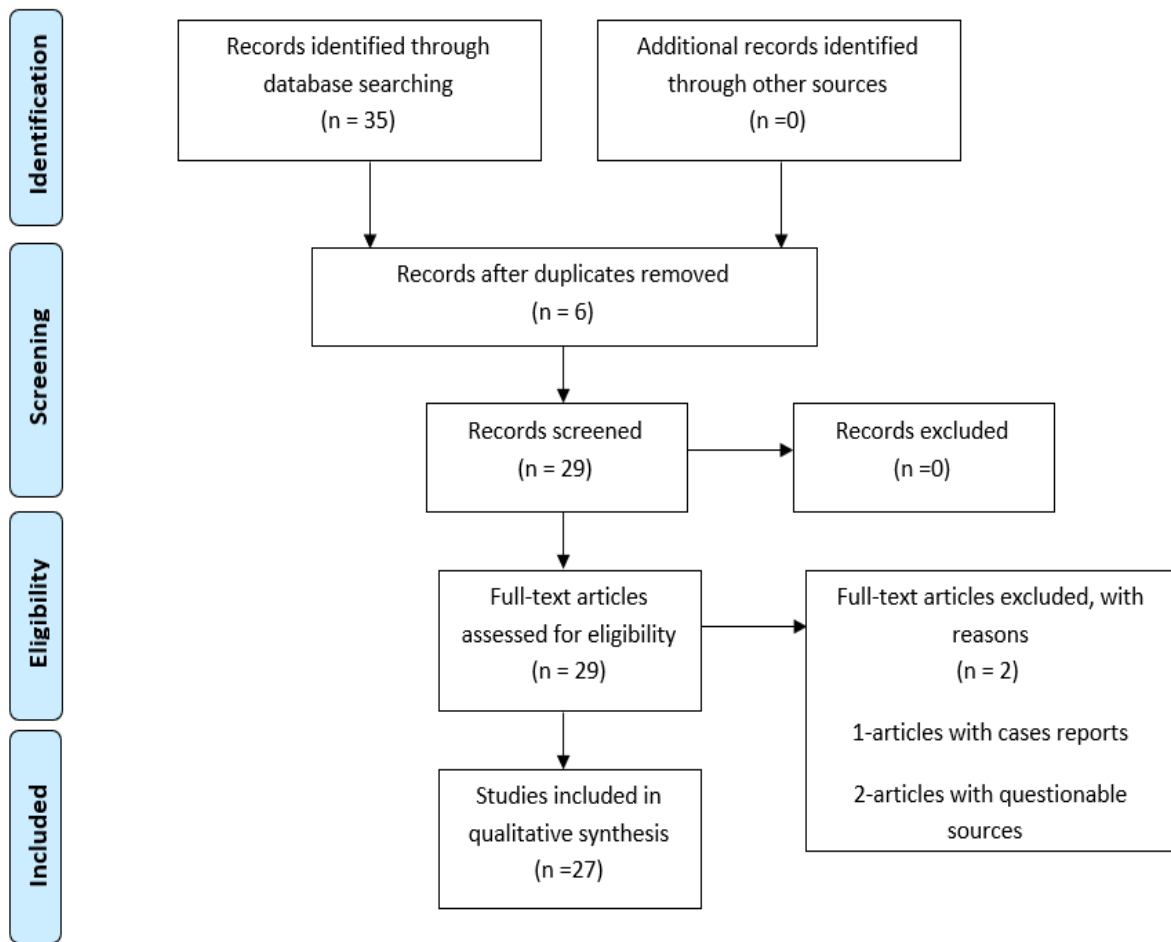
Intracanal medication TAP (ciprofloxacin, metronidazole, minocycline) used with sufficient concentration to avoid the toxicity of the host stem cell.<sup>13-20</sup> The paste contains 200 mg ciprofloxacin, 500 mg metronidazole, and 100 mg minocycline.<sup>21</sup> Modified TAP in which minocycline is replaced with non-discoloring medicaments like clarithromycin or fosfomycin or cefuroxime or Arestin or cefaclor.<sup>22, 23</sup>

Calcium hydroxide does not cause discoloration and has been shown to be as effective as antibiotics in promoting root lengthening and thickening.

The promoting blood clot in REP by file or explorer to induce bleeding into the canal space use anesthesia with 3% mepivacaine without vasoconstrictor. It takes about 15mins to allow the blood to clot and stabilize below the cement enamel junction. Use intracanal pressure with a sterile pellet of cotton soaked in a sterile saline solution. Once a blood clot or scaffold is inside the canal, a coronal barrier is positioned to prevent coronal leakage of microorganism placement 4 mm glass ionomer layer each 3-6 months. However, due to the heterogeneity of the examined studies, it was not possible to quantitatively evaluate the effect of the irrigants and intracanal medicines, their concentrations and the time for application after RET on the medical, radiographic and histological tests.

**CONCLUSION**

Regenerative endodontic treatment is based on the concept of tissue engineering technology to regenerate the dentine-pulp complex in the canal space of immature permanent teeth damaged by caries or trauma. The growth of the arrested tooth root is thus restored. RET will remove the symptoms/signs of the patient and relieve apical periodontitis. The primary objective of endodontic therapy is continued root development (thickening and/or apical closure of canal walls). The procedures can do by removing infection, root canal disinfection, and filling of the canal space with biocompatible foreign material. Subsequently, to accomplish of the regenerative endodontic treatment procedure, selected case and along term follow-up are viewed as significant.



Figure

Material	Use	Advantage	Disadvantage
1-Ciprofloxacin, metronidazole	As intracanal medication		
2-TAP (ciprofloxacin, metronidazole, minocycline)	As intracanal medication Hoshino's paste. The paste contains 200 mg ciprofloxacin, 500 mg metronidazole, and 100 mg minocycline	<ul style="list-style-type: none"> <li>- Use it with adequate concentration to have antibacterial properties and prevent toxicity of host stem cell</li> <li>- Presenting biocompatibility and adequate antimicrobial capacity</li> <li>- Able to perform root canal system disinfection</li> <li>- Can increase thickness of dental wall</li> </ul>	<ul style="list-style-type: none"> <li>- Resistance against bacteria, cause discoloration, allergic reaction</li> </ul>
3-Sodium hypochloride 1,5 to 5,25(20 ML)	Is the most used irrigating solution in concentrations ranging from 1% to 6%		<ul style="list-style-type: none"> <li>- When use it with high concentration can kill SCAP</li> </ul>
4-Calcium hydroxide	Used as an intracanal medicament for further disinfection	<ul style="list-style-type: none"> <li>- Limit bacterial growth</li> <li>- Did not cause discoloration</li> <li>- Proved to be equally as effective as the antibiotics at promoting root lengthening and thickening</li> </ul>	<ul style="list-style-type: none"> <li>- High pH lead to death of SCAP</li> </ul>
5-Bonding agent and composite resin	As seal to the canal	<ul style="list-style-type: none"> <li>- To avoid discoloration</li> </ul>	
6-MTA	Apply it above blood clot	<ul style="list-style-type: none"> <li>- To permit root development 1-2 mm apical to CEJ</li> <li>- Reduced the possibility of tooth fractures in the long-term comparing it to calcium hydroxide.</li> <li>- More biocompatible than Super EBA (Reinforced zinc-oxide cement based on eugenol and ethoxy benzoic acid)</li> <li>- 95% survival rate for the</li> <li>- MTA apical plug apexification with trioxide mineral aggregate (MTA)</li> <li>- Applied directly to human tissues, it forms calcium hydroxide that releases calcium ions for cell attachment and proliferation</li> <li>- Ability to seal in moist in environment less toxic</li> <li>- May also favor stem cell recruitment</li> <li>- Release of bioactive molecules</li> </ul>	<ul style="list-style-type: none"> <li>- Discoloration when placed on the top of blood clot</li> </ul>
7-Chlorhexidine gluconate	<ul style="list-style-type: none"> <li>- Used after NaOCL</li> <li>- Using as coronal irrigation</li> <li>- The use of chlorhexidine has been shown to inhibit stem cell differentiation and is no longer employed</li> </ul>		<ul style="list-style-type: none"> <li>- Not appear as best choice to irrigate RET</li> </ul>

**Table**

## REFERENCES

1. Östby BN. The role of the blood clot in endodontic therapy an experimental histologic study. *Acta Odontologica Scandinavica* 1961;19(3-4):323-53.
2. Diogenes A, Ruparel NB, Shiloah Y, Hargreaves KM. Regenerative endodontics: a way forward. *The Journal of the American Dental Association* 2016;147(5):372-80.
3. Chueh L-H, Huang GT-J. Immature teeth with periradicular periodontitis or abscess undergoing apexogenesis: a paradigm shift. *Journal of endodontics* 2006;32(12):1205-13.
4. Siqueira Jr J, Rôças I, Ricucci D, Hülsmann M. Causes and management of post-treatment apical periodontitis. *British dental journal* 2014;216(6):305.
5. Heyeraas K, Berggreen E. Interstitial fluid pressure in normal and inflamed pulp. *Critical Reviews in Oral Biology & Medicine* 1999;10(3):328-36.
6. Hoshino E, Kurihara-Ando N, Sato I, et al. In-vitro antibacterial susceptibility of bacteria taken from infected root dentine to a mixture of ciprofloxacin, metronidazole and minocycline. *International endodontic journal* 1996;29(2):125-30.
7. Hargreaves KM, Diogenes A, Teixeira FB. Treatment options: biological basis of regenerative endodontic procedures. *Pediatric dentistry* 2013;35(2):129-40.
8. Kontakiotis EG, Filippatos CG, Tzanetakakis GN, Agrafioti A. Regenerative endodontic therapy: a data analysis of clinical protocols. *Journal of endodontics* 2015;41(2):146-54.
9. Zehnder M. Root canal irrigants. *Journal of endodontics* 2006;32(5):389-98.
10. Mohammadi Z. Chlorhexidine gluconate, its properties and applications in endodontics. *Iranian endodontic journal* 2008;2(4):113.
11. Aksel H, Serper A. Recent considerations in regenerative endodontic treatment approaches. *Journal of Dental Sciences* 2014;9(3):207-13.
12. Martin DE, De Almeida JFA, Henry MA, et al. Concentration-dependent effect of sodium hypochlorite on stem cells of apical papilla survival and differentiation. *Journal of endodontics* 2014;40(1):51-55.
13. Banchs F, Trope M. Revascularization of immature permanent teeth with apical periodontitis: new treatment protocol? *Journal of endodontics* 2004;30(4):196-200.
14. Jung I-Y, Lee S-J, Hargreaves KM. Biologically based treatment of immature permanent teeth with pulpal necrosis: a case series. *Journal of endodontics* 2008;34(7):876-87.
15. Reynolds K, Johnson J, Cohenca N. Pulp revascularization of necrotic bilateral bicuspid using a modified novel technique to eliminate potential coronal discoloration: a case report. *International endodontic journal* 2009;42(1):84-92.
16. Torabinejad M, Turman M. Revitalization of tooth with necrotic pulp and open apex by using platelet-rich plasma: a case report. *Journal of endodontics* 2011;37(2):265-68.
17. Martin G, Ricucci D, Gibbs JL, Lin LM. Histological findings of revascularized/revitalized immature permanent molar with apical periodontitis using platelet-rich plasma. *Journal of endodontics* 2013;39(1):138-44.
18. Becerra P, Ricucci D, Loghin S, Gibbs JL, Lin LM. Histologic study of a human immature permanent premolar with chronic apical abscess after revascularization/revitalization. *Journal of endodontics* 2014;40(1):133-39.
19. Petrino J. Revascularization of necrotic pulp of immature teeth with apical periodontitis. *Northwest dentistry* 2007;86(3):33-35.
20. Dabbagh B, Alvaro E, Vu D-D, Rizkallah J, Schwartz S. Clinical complications in the revascularization of immature necrotic permanent teeth. *Pediatric dentistry* 2012;34(5):414-17.
21. Sato I, Ando-Kurihara N, Kota K, Iwaku M, Hoshino E. Sterilization of infected root-canal dentine by topical application of a mixture of ciprofloxacin, metronidazole and minocycline in situ. *International endodontic journal* 1996;29(2):118-24.
22. Thibodeau B, Trope M. Pulp revascularization of a necrotic infected immature permanent tooth: case report and review of the literature. *Pediatric dentistry* 2007;29(1):47-50.
23. Bezgin T, Sönmez H. Review of current concepts of revascularization/revitalization. *Dental Traumatology* 2015;31(4):267-73.