

Original Research

Comparison of different condensation techniques in pulpectomy cases

¹Dr. Milind Rajan, ²Dr. Anesha Sebastian, ³Dr. Sanmati S Varne, ⁴Dr. Lagushetty Sravan, ⁵Dr. Jyoti Goyal, ⁶Dr. Iram Ahsan

^{1,2}PG 3rd year, Department of Pediatric and Preventive Dentistry Coorg institute of Dental Sciences Virajpet, Karnataka;

³PG 2nd year, Department of Prosthodontics and Implantology Coorg institute of Dental Sciences Virajpet, Karnataka;

⁴BDS, MNR Dental College and Hospital, Sangareddy, Telangana;

⁵BDS, MDS (Public Health Dentistry) Senior Research Fellow (SRF), Department of Pediatric Surgery, All India Institute of Medical Sciences (AIIMS), Ansari Nagar, New Delhi;

⁶Post Graduate Student, Department of Public Health Dentistry, I.T.S Centre for Dental Studies and Research, Muradnagar, Uttar Pradesh, India

ABSTRACT:

Background: Pulpectomy is a root canal procedure for pulp tissue that is irreversibly infected or necrotic. The present study compared the efficacy of different obturating methods used in primary teeth. **Materials & Methods:** 50 mandibular primary teeth requiring pulpectomy of both genders were divided into 2 groups of 25 each. A standardized pulpectomy procedure was performed in all teeth. In group I, teeth were obturated with a disposable syringe (Dispovan) and in group II using lentulo spiral (Mani). **Results:** Level of obturation was less or equal to half the root length seen in 6 in group I and 3 in group II, more than half the root length 7 in group I and 13 in group II, optimal filing 9 in group I and 5 in group II and filling extruding from the apex 3 in group I and 4 in group II. There were 0 void seen in 15 in group I and 9 in group II and 1 voids seen 10 in group I and 16 in group II teeth. The difference was significant ($P < 0.05$). **Conclusion:** Both techniques were comparable in terms of obturation in primary molars.

Key words: disposable syringe, lentulo spiral, obturation

Received: 4 January, 2021

Accepted: 26 February, 2021

Corresponding author: Dr. Milind Rajan, PG 3rd year, Department of Pediatric and Preventive Dentistry Coorg institute of Dental Sciences Virajpet, Karnataka, India

This article may be cited as: Rajan M, Sebastian A, Varne SS, Sravan L, Goyal J, Ahsan I. Comparison of different condensation techniques in pulpectomy cases. Int J Res Health Allied Sci 2021; 7(2):xx-xx.

INTRODUCTION

Pulpectomy is a root canal procedure for pulp tissue that is irreversibly infected or necrotic. The root canals are debrided and shaped and canals are dried and obturated with a resorbable material.¹ Pulpectomy of primary teeth is indicated when the inflammation of the pulpal tissue involves the radicular pulp or when nonvital tooth is diagnosed.² Pulpectomy helps in preserving a pulpally involved primary tooth by extirpating the diseased pulp associated with microorganism and debris from the canal and obturating with an antibacterial resorbable filling material.³ The ultimate goal of pulpectomy is to

achieve good hermetic seal which depends on various factors such as good biomechanical preparation, types of obturating material used and achievement of minimum voids. Obturation of the canal creates a fluid tight seal along the length of the root from the coronal opening to the apical system and eliminating all portals of entry between the periodontium and the root canal system.⁴

Different obturation techniques to fill the primary root canal include conventional manual incremental lateral condensation by amalgam pluggers, tuberculin syringe, disposable injection technique, navi tip, hand-held, rotary lentulospiral, jiffy tubes, endodontic

pressure syringe, past inject, etc.⁵ The lentulo spiral is the most commonly used instrument as the root canal paste carrier. The obturating paste can be filled by means of a manual lentulo spiral or mounted on micromotor handpiece. The process is easy and economical. Filling the root canal does not produce a densely compacted root canal filling and much reliance is placed on adherence of the paste to the walls of the canal.⁶ The present study compared the efficacy of different obturating methods used in primary teeth.

MATERIALS & METHODS

The present study comprised of 50 mandibular primary teeth requiring pulpectomy of both genders.

Parents were made aware of the study and their consent was obtained.

Data such as name, age, gender etc. was recorded. Patients were divided into 2 groups of 25 each. A standardized pulpectomy procedure was performed in all teeth. In group I, teeth were obturated with a disposable syringe (Dispovan) and in group II using lentulo spiral (Mani).

Postoperative IOPA radiographs of each tooth were obtained for each tooth and postoperative evaluation was done for quality of canal obturation, presence of voids using postoperative radiographs following obturation of teeth. Results thus obtained were statistically analyzed. P value less than 0.05 was considered significant.

RESULTS

Table I Distribution of teeth

Groups	Group I	Group II
Method	Disposable syringe	Lentulo spiral
Number	25	25

Table I shows methods of obturation used for the study.

Table II Comparison of level of obturation

Level of obturation	Group I	Group II	P value
Less or equal to half the root length	6	3	0.05
More than half the root length	7	13	0.01
Optimal filing	9	5	0.04
Filling extruding from the apex	3	4	0.05

Table II, graph I shows that level of obturation was less or equal to half the root length seen in 6 in group I and 3 in group II, more than half the root length 7 in group I and 13 in group II, optimal filing 9 in group I and 5 in group II and filling extruding from the apex 3 in group I and 4 in group II. The difference was significant (P< 0.05).

Graph I Comparison of level of obturation

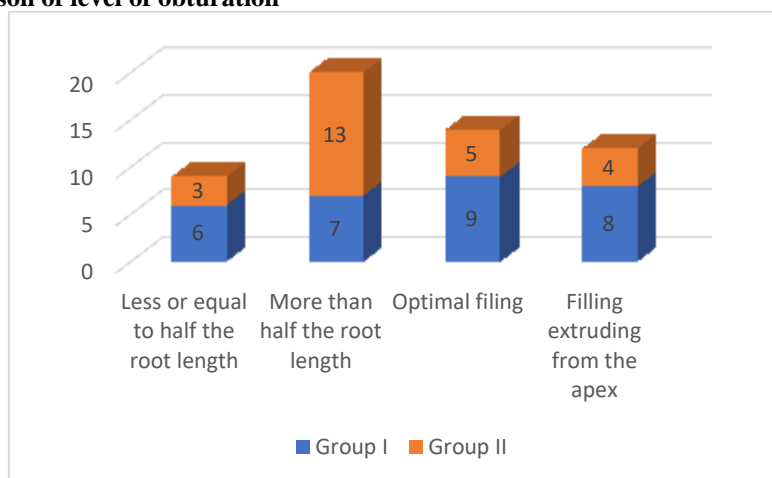
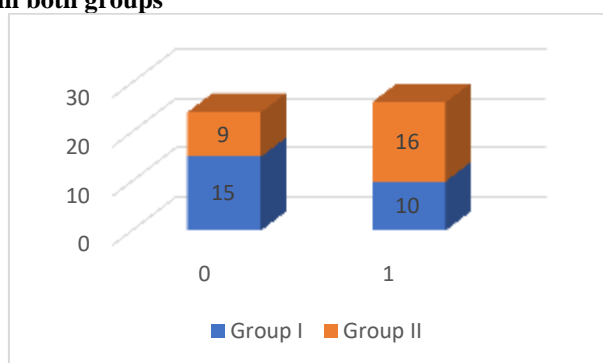


Table III Voids in canals in both groups

Voids	Group I	Group II	P value
0	15	9	0.03
1	10	16	0.02

Table III, graph II shows that there were 0 void seen in 15 in group I and 9 in group II and 1 voids seen 10 in group I and 16 in group II teeth. The difference was significant ($P < 0.05$).

Graph II Voids in canals in both groups

DISCUSSION

Pulpectomy is the procedure of extirpating the diseased pulp associated with microorganism and debris from the canal and obturating with an antibacterial resorbable filling material and it is indicated when the inflammation of the pulpal tissue involves the radicular pulp or when nonvital tooth is diagnosed.⁷ Ultimately, pulpectomy is needed to achieve good hermetic seal which depends on various factors such a good biomechanical preparation, type of obturating material used and achievement of minimum voids. Obturating the canal creates a fluid tight seal along the length of the root from the coronal opening.⁸ The present study compared the efficacy of different obturating methods used in primary teeth.

In present study, level of obturation was less or equal to half the root length seen in 6 in group I and 3 in group II, more than half the root length 7 in group I and 13 in group II, optimal filing 9 in group I and 5 in group II and filling extruding from the apex 3 in group I and 4 in group II. Gandhi et al⁹ evaluated and compared the efficacy of different obturating methods used in primary teeth. Forty- one patients aged four to nine years with a total of 60 teeth were selected. Out of the 60 teeth, 32 were primary mandibular first molars and 28 were primary mandibular second molars, the sample was randomly divided into three groups. Disposable syringe, lentulo spiral and past inject were used for obturation. Postoperative evaluation was done for; quality of canal obturation, presence of voids using postoperative radiographs following obturation of teeth. Among the three groups of the study, past inject exhibited the maximum number of optimally filled canals. Maximum number of underfilled canals was found with lentulospiral, and the maximum number of overfilled canals was seen

with disposable syringe. Least number of voids was observed in canals filled with the past inject technique and disposable syringe.

We observed that there were 1 void seen in 15 in group I and 9 in group II and 2 voids seen 10 in group I and 16 in group II teeth. Dandashi et al¹⁰ in vitro evaluated the obturation methods in deciduous teeth and concluded that the lentulospiral mounted in a slow speed handpiece show superior root canal filling in straight and curved root canals of deciduous teeth. No significant differences were demonstrated between the pressure syringe and lentulo spiral techniques while filling straight canals.

Nagarathna et al¹¹ determined the efficacy of modified disposable syringe technique in root canals of primary molars using digital radiography when obturated with endoflas. A total of 60 primary maxillary and mandibular molars were selected in the age group of 4–8 years and randomly divided into two groups. The teeth were obturated with handheld lentulospiral and a modified disposable syringe techniques. Postoperative radiographic evaluation was done for quality of fill and voids using digital radiography. No statistically significant difference between quality of obturation using hand-held lentulospiral and modified disposable syringe ($P < 0.05$) was observed. Optimal obturation was achieved in both techniques; however, voids in obturation were not significant.

Fuks AB et al¹² in their study endoflas was used as a filling material. The resorption of the material was limited to the excess extruded extra-radicularly and it does not get depleted intraradicularly. The over pushing of the root canal filling material in primary teeth is unavoidable in some cases because of the thin dentinal walls of the root canals towards the inter-

radicular areas, which may give way during filing of root canals.

CONCLUSION

Authors found that both techniques were comparable in terms of obturation in primary molars.

REFERENCES

1. Subba Reddy W, Shakunthala B. Comparative assessment of three obturating techniques in primary molars: An in vivo study. *Endodontology*. 1997;9:13-16.
2. Guelmann M, McEachern M, Turner C. Pulpectomies in primary incisors using three delivery systems: an in vitro study. *J Clin Paediatr Dent*. 2004;28: 323-26.
3. Sari S, Okte Z. Success rate of Sealapex in root canal treatment for primary teeth: a 3-year follow-up. *Oral Surg Oral Med Oral Path Oral Radiol Endod*. 2008;105:e93-e96.
4. Kositbowornchai S, Hanwachirapong D, Somsopon R, Pirmsinthavee S, Sooksuntisakoonchai N. Ex vivo comparison of digital images with conventional radiographs for detection of simulated voids in root canal filling material. *Int Endod J*. 2006;39:287-92.
5. Huybrechts B, Bud M, Bregmans L, Lambrechts P, Jacobs R. Void detection in root fillings using intraoral analogue, intraoral digital, and cone beam CT images. *Int Endod J*. 2009;42:675-85.
6. Kahn FH, Rosenberg PA, Schertzer L, Korthals G, Nguyen PN. An in vitro evaluation of sealer placement methods. *Int Endod J*. 1997;30:181-86.
7. Grover R, Mehra M, Pandit IK, Srivastava N, Gugnani N, Gupta M. Clinical efficacy of various root canal obturating methods in primary teeth: A comparative study. *Eur J Paediatr Dent*. 2013;14(2):104-08.
8. Serene TP, Vesely J, Boackle RJ. Complement activation as a possible in vitro indication of the inflammatory potential of endodontic materials. *Oral Surg*. 1988;65:354.
9. Gandhi M, Tandon S, Vijay A, Kalia G, Rathore K. Clinical assessment of various obturating techniques for primary teeth: A comparative study. *Journal of clinical and diagnostic research: JCDR*. 2017;11(7):48.
10. Dandashi MB, Nazif MM, Zullo T, Elliott MA, Schneider LG, Czonstkowsky M. An in vitro comparison of three endodontic techniques for primary incisors. *Pediatr Dent* 1993;15(4):254-256.20.
11. Nagarathna C, Vishwanathan S, Krishnamurthy NH, Bhat PK. Primary molar pulpectomy using two different obturation techniques: A clinical study. *Contemp Clin Dent* 2018;9:231-6.
12. Fuks AB, Eielman E, Pauker N. Root canal filling with endoflas in primary teeth: Aretrospective study. *J Clin Paediatr Dent*. 2002;27(1):41-46.